

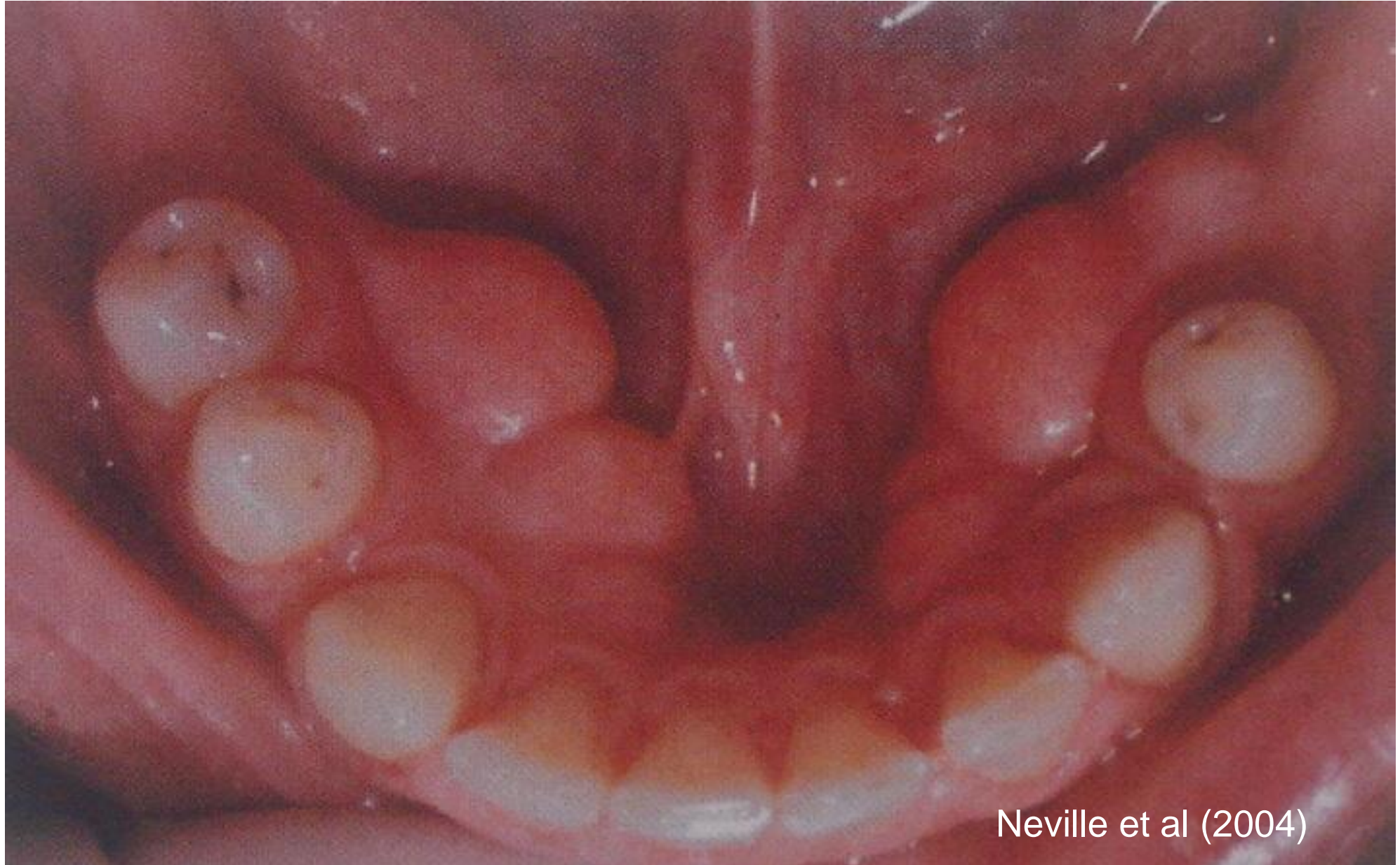
CEO-ESTOMATOLOGIA

Variações Anatômicas da Mucosa Bucal

Variações anatômicas da mucosa bucal

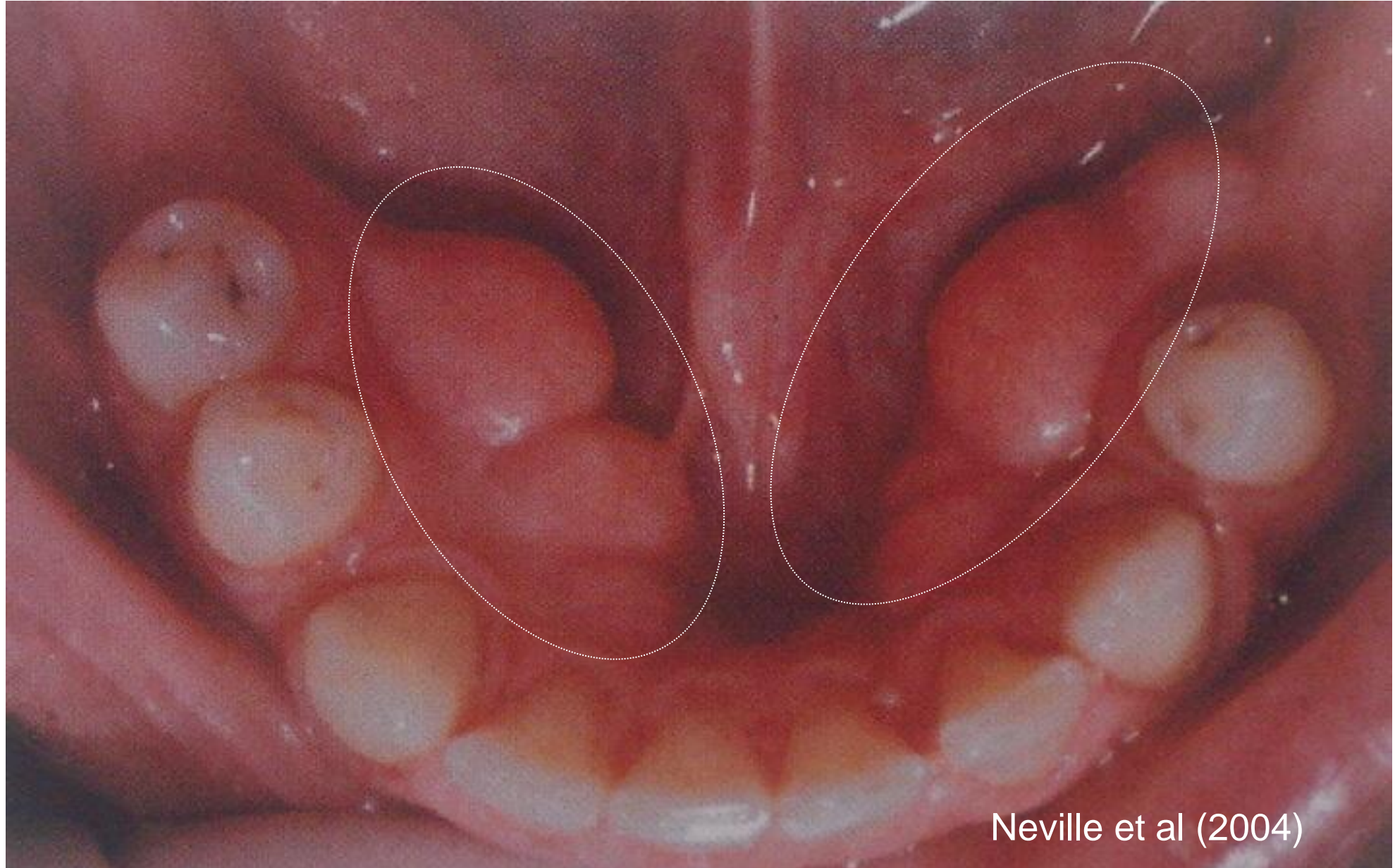
- Tórus
- Grânulos de Fordyce
- Papila parotídea
- Carúnculas sublinguais
- Papilas circunvaladas
- Papilas foliáceas
- Pregas fimbriadas
- Linha alba
- Varicosidades linguais

Tórus mandibular



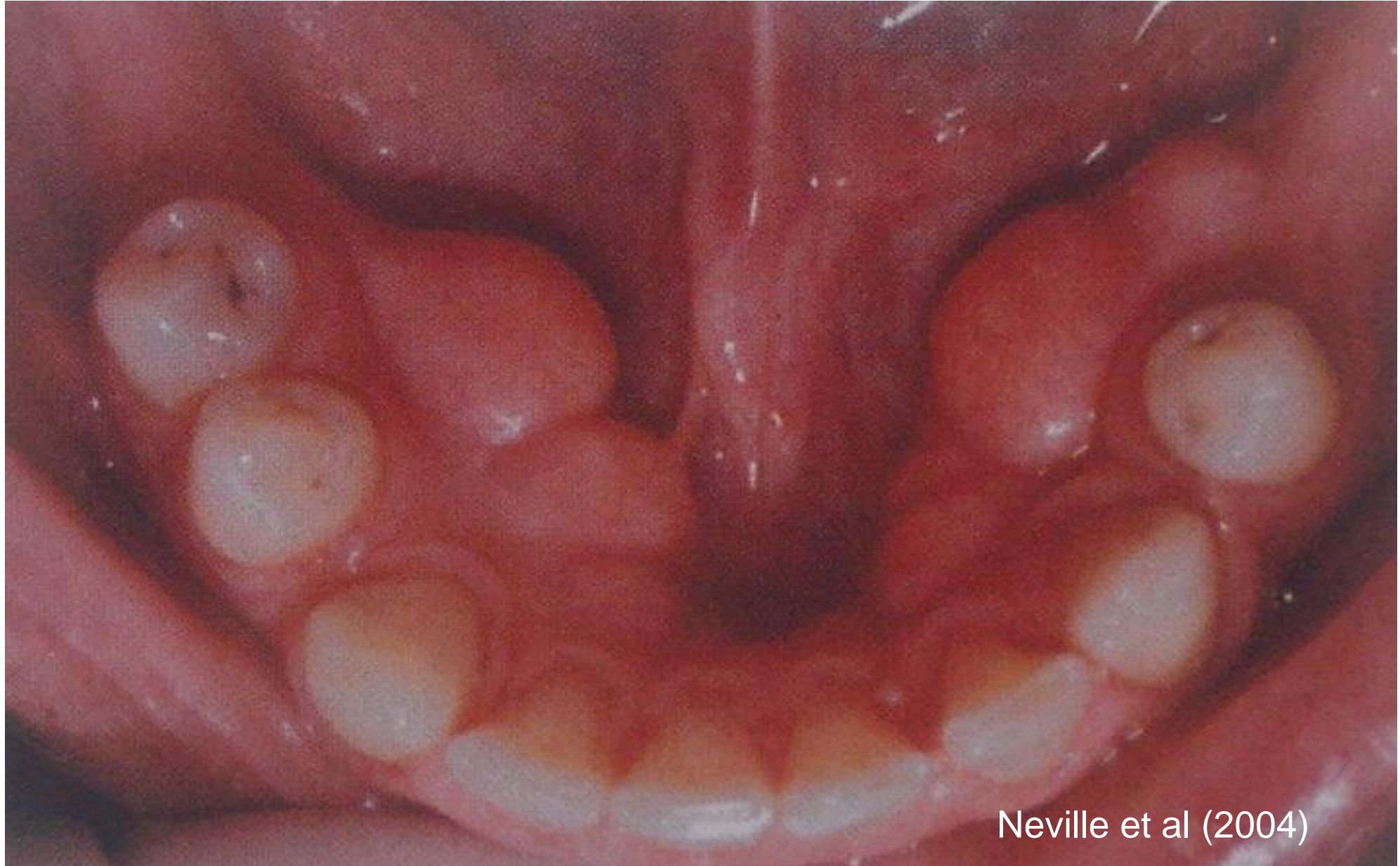
Neville et al (2004)

Tórus mandibular



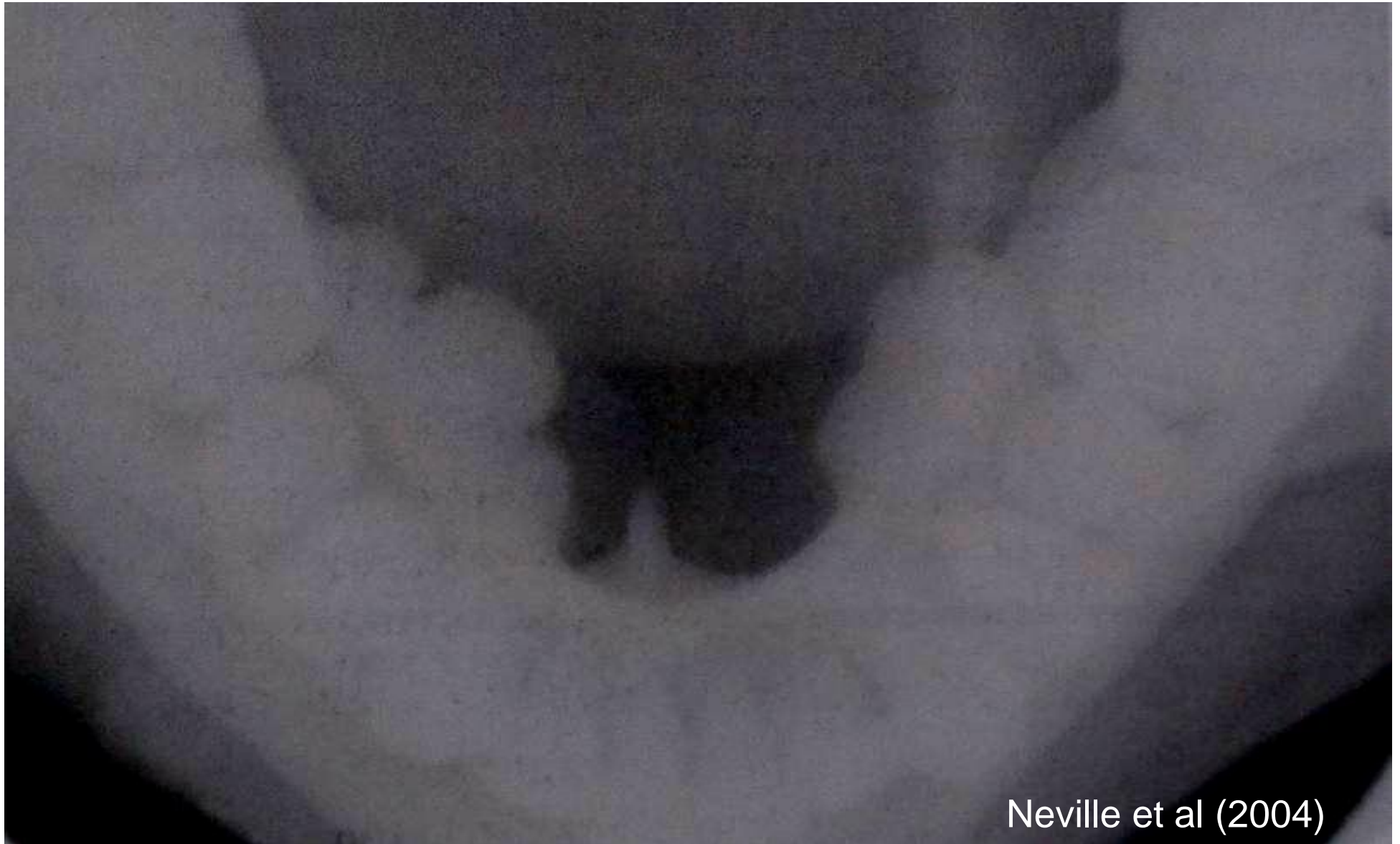Neville et al (2004)

Tórus mandibular



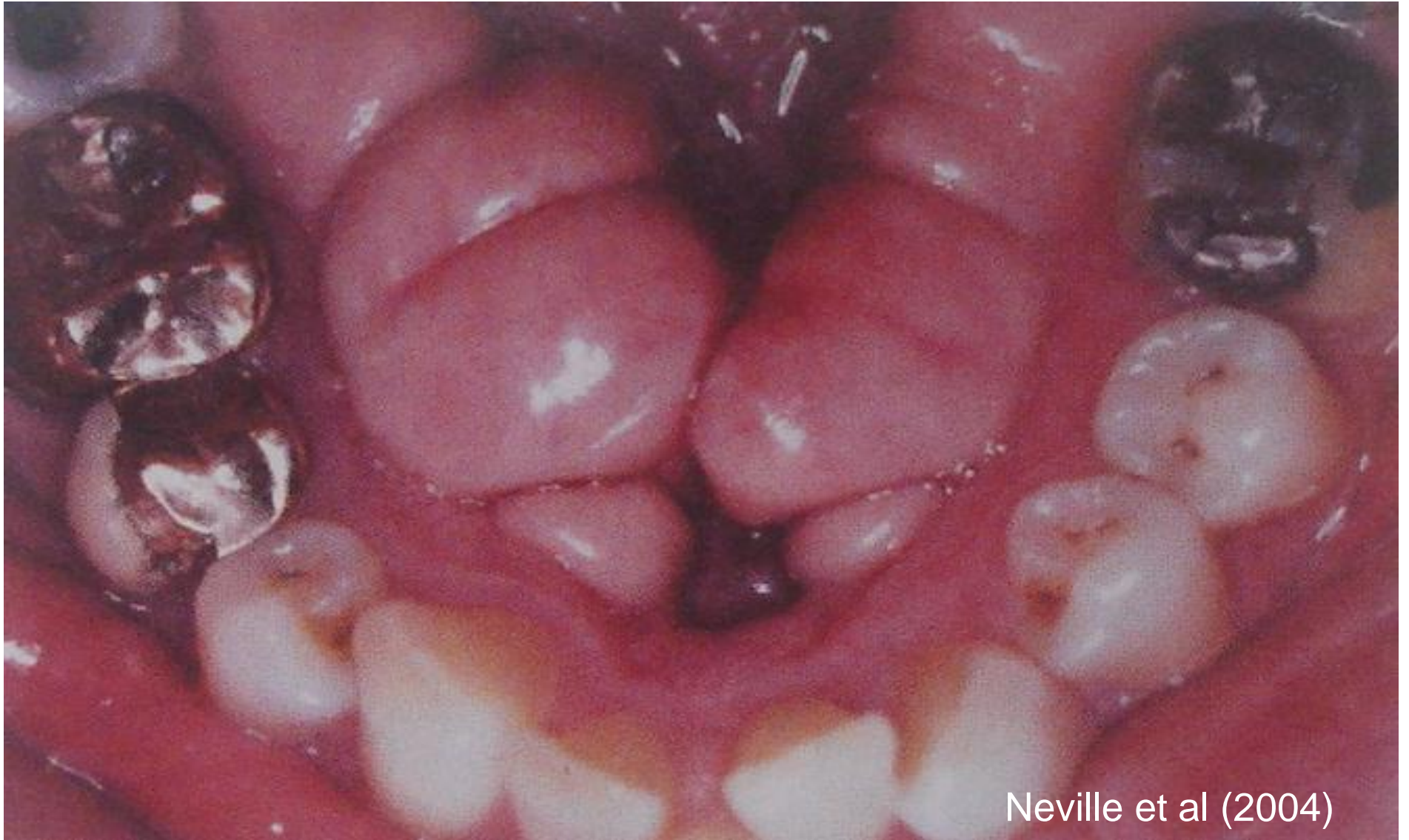Neville et al (2004)

Tórus mandibular



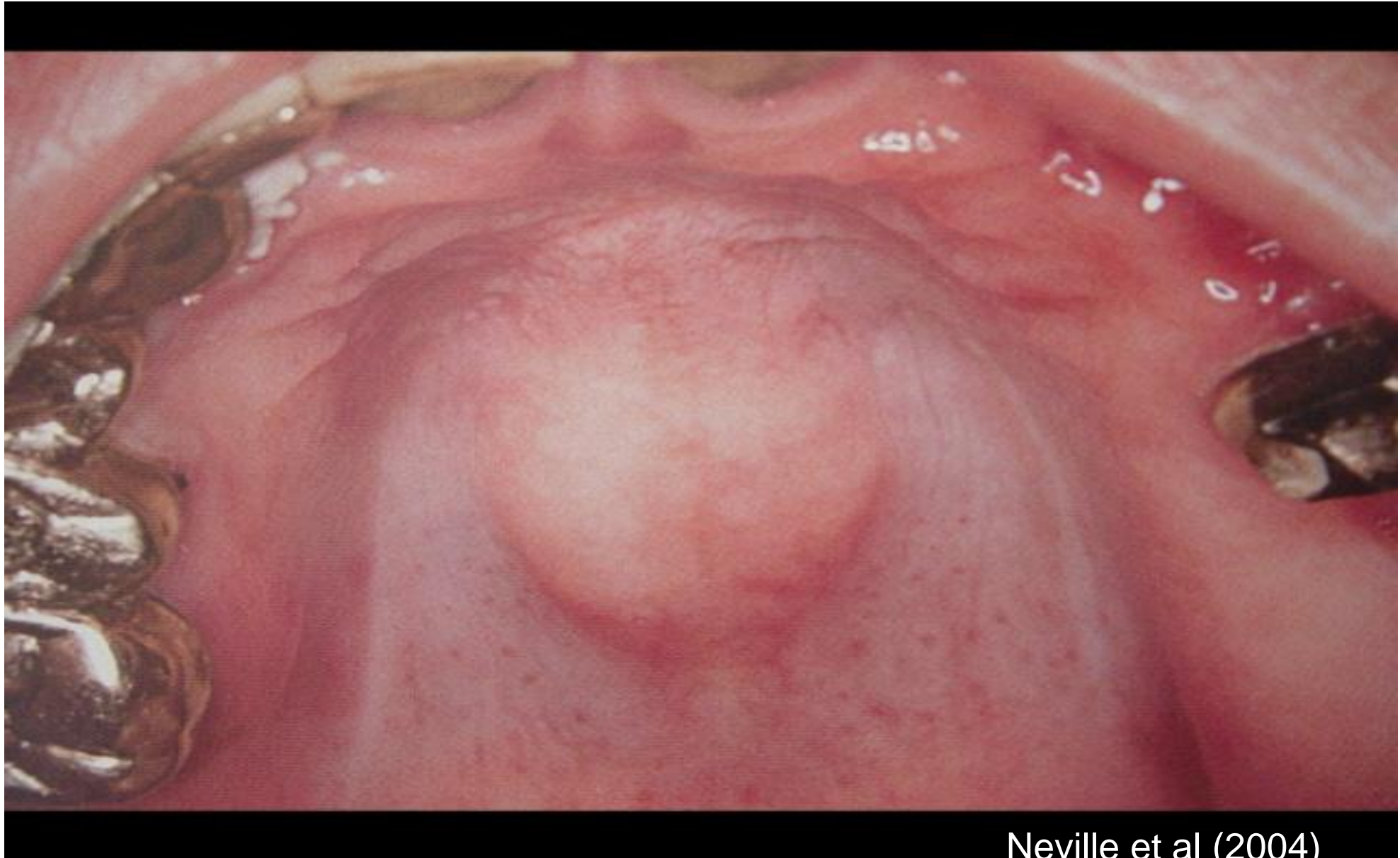
Neville et al (2004)

Tórus mandibular



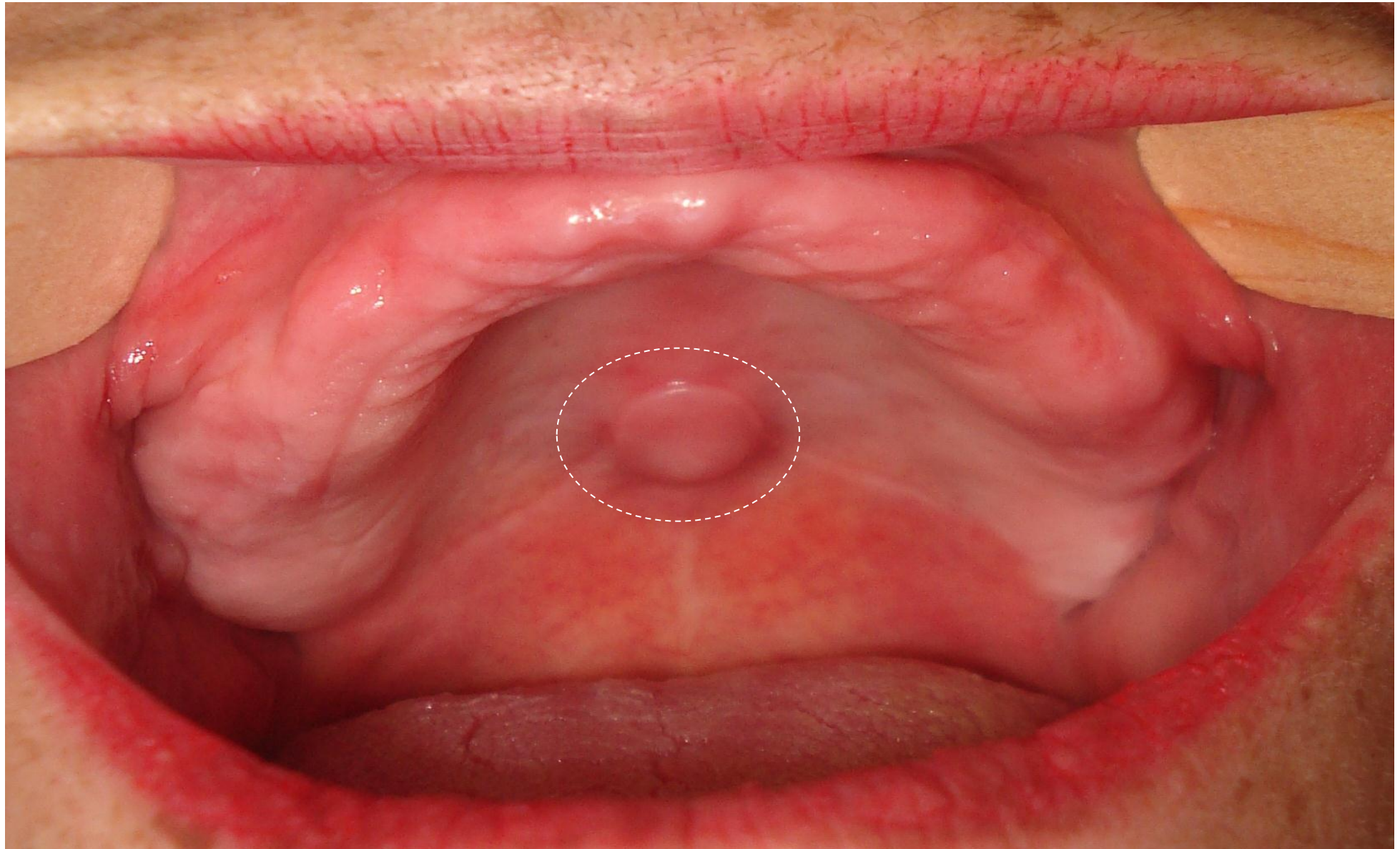
Neville et al (2004)

Tórus palatino

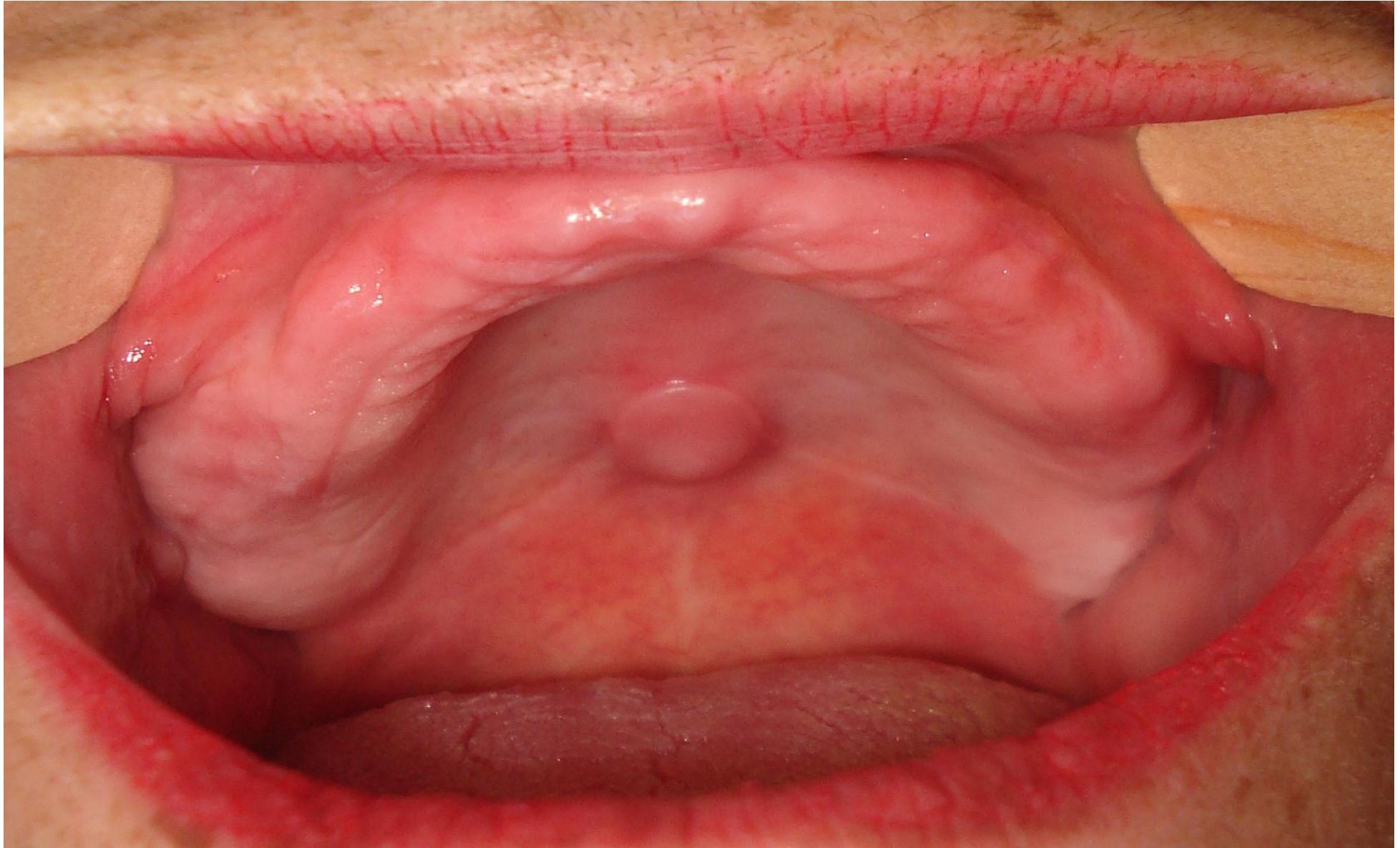

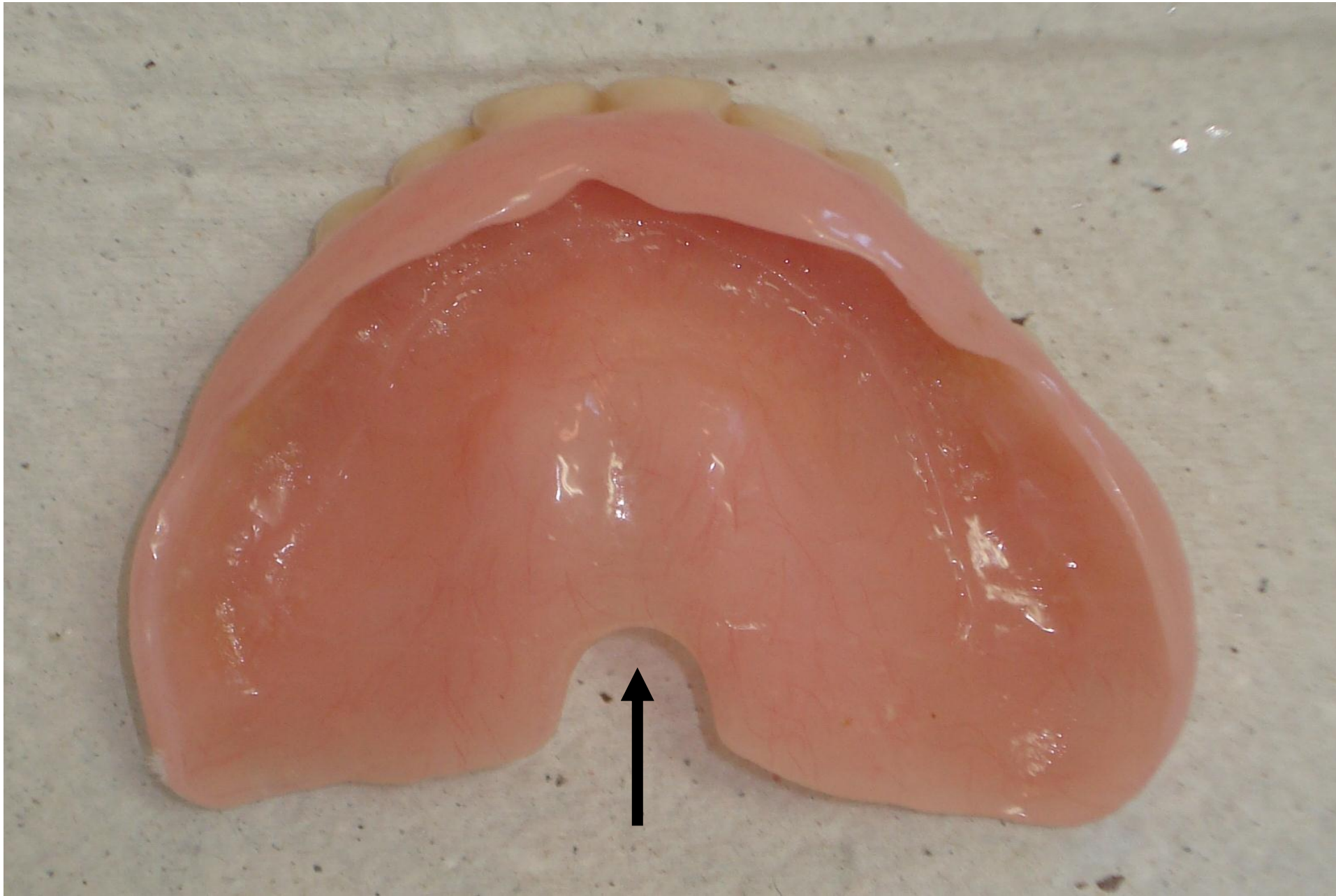
Neville et al (2004)

Tórus palatino

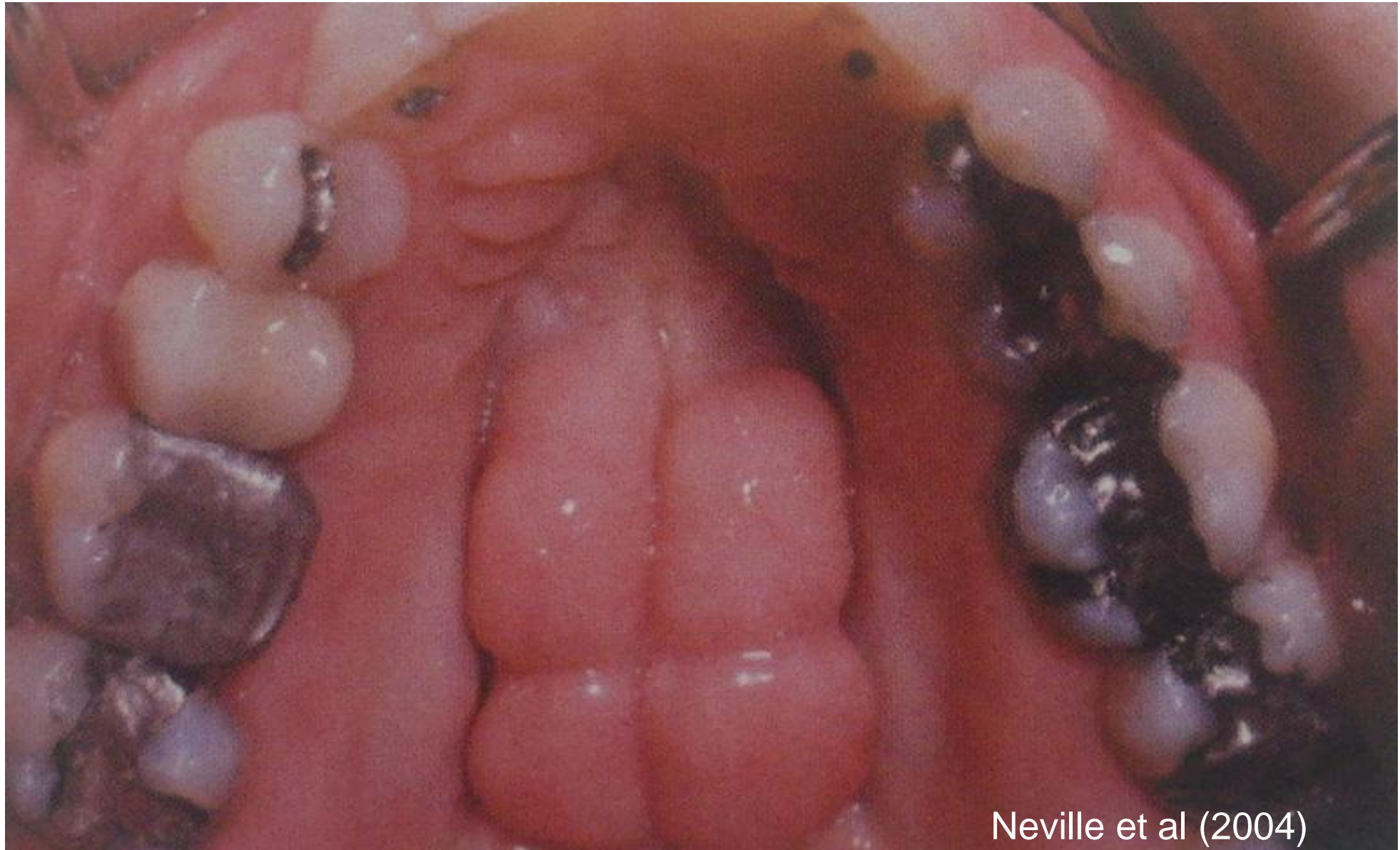

Tórus palatino



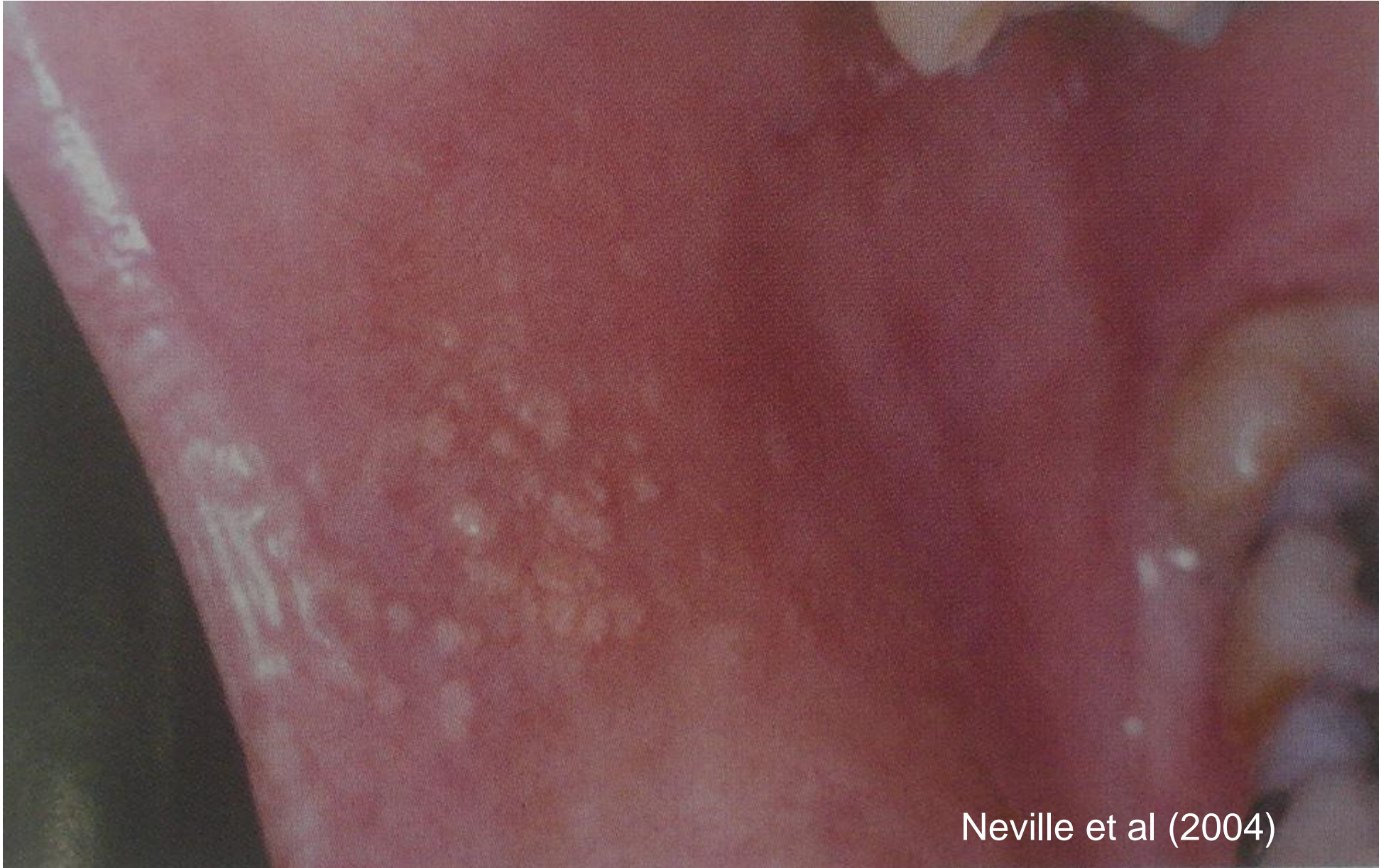

Tórus palatino



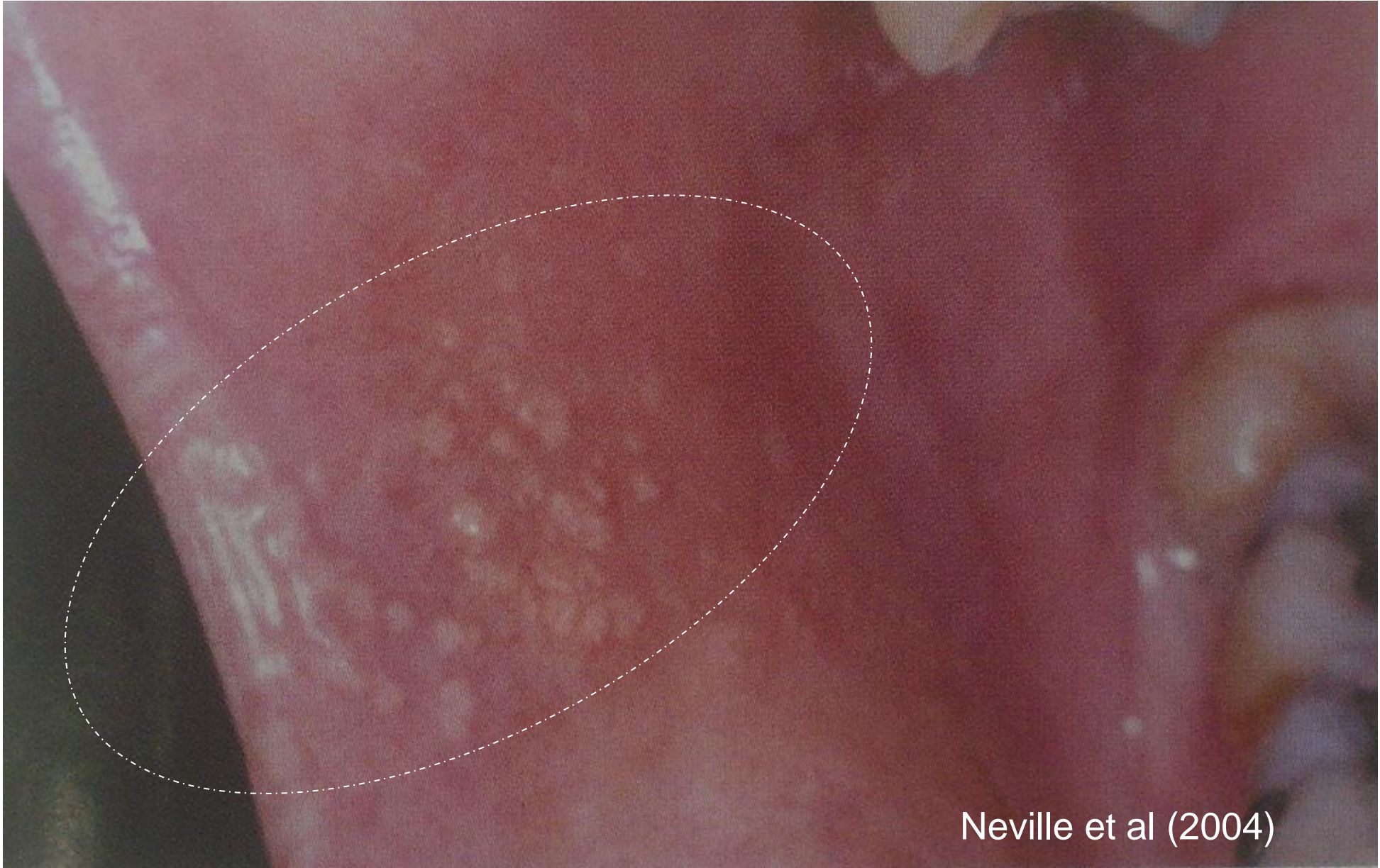
Neville et al (2004)

Grânulos de Fordyce



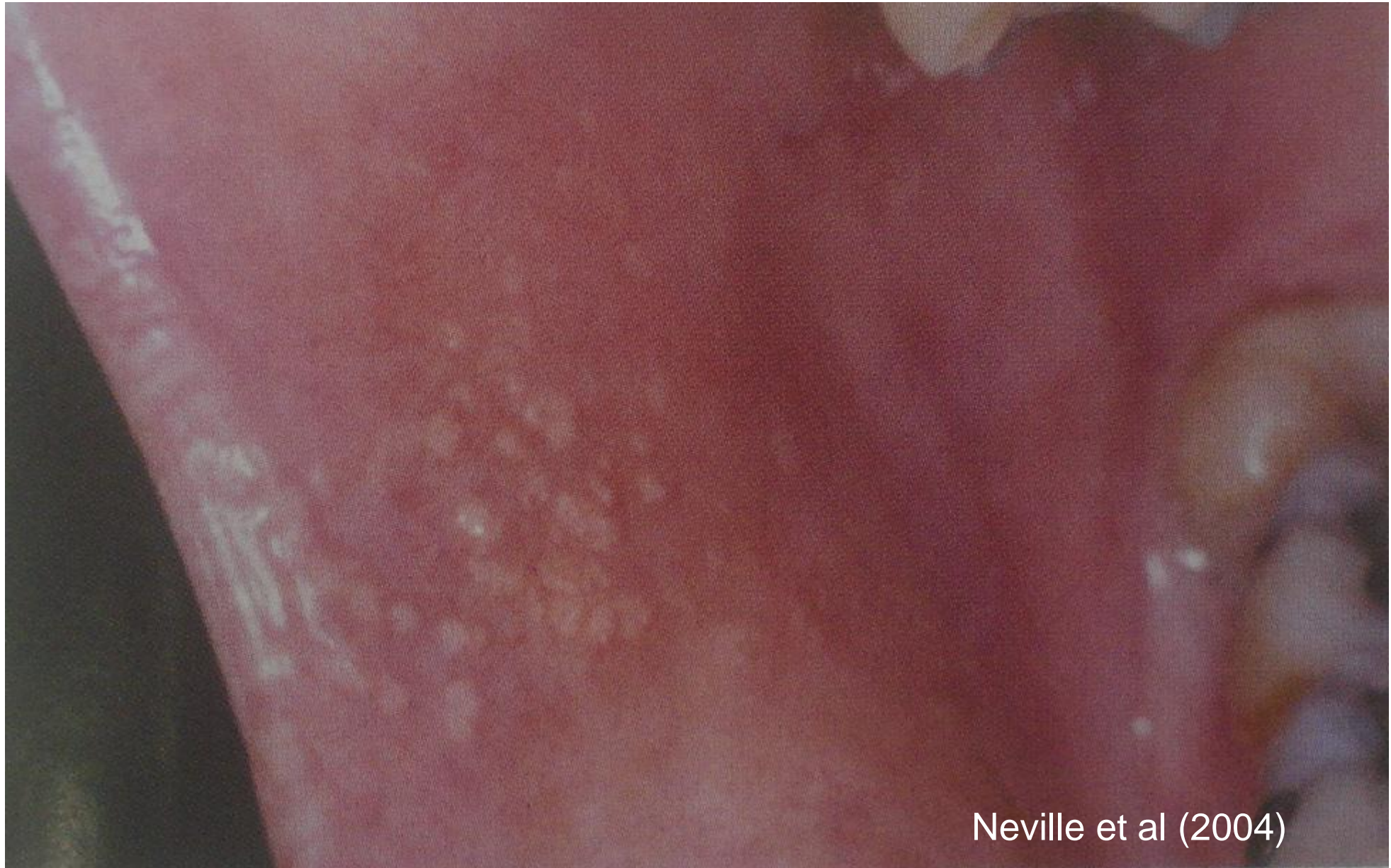Neville et al (2004)

Grânulos de Fordyce



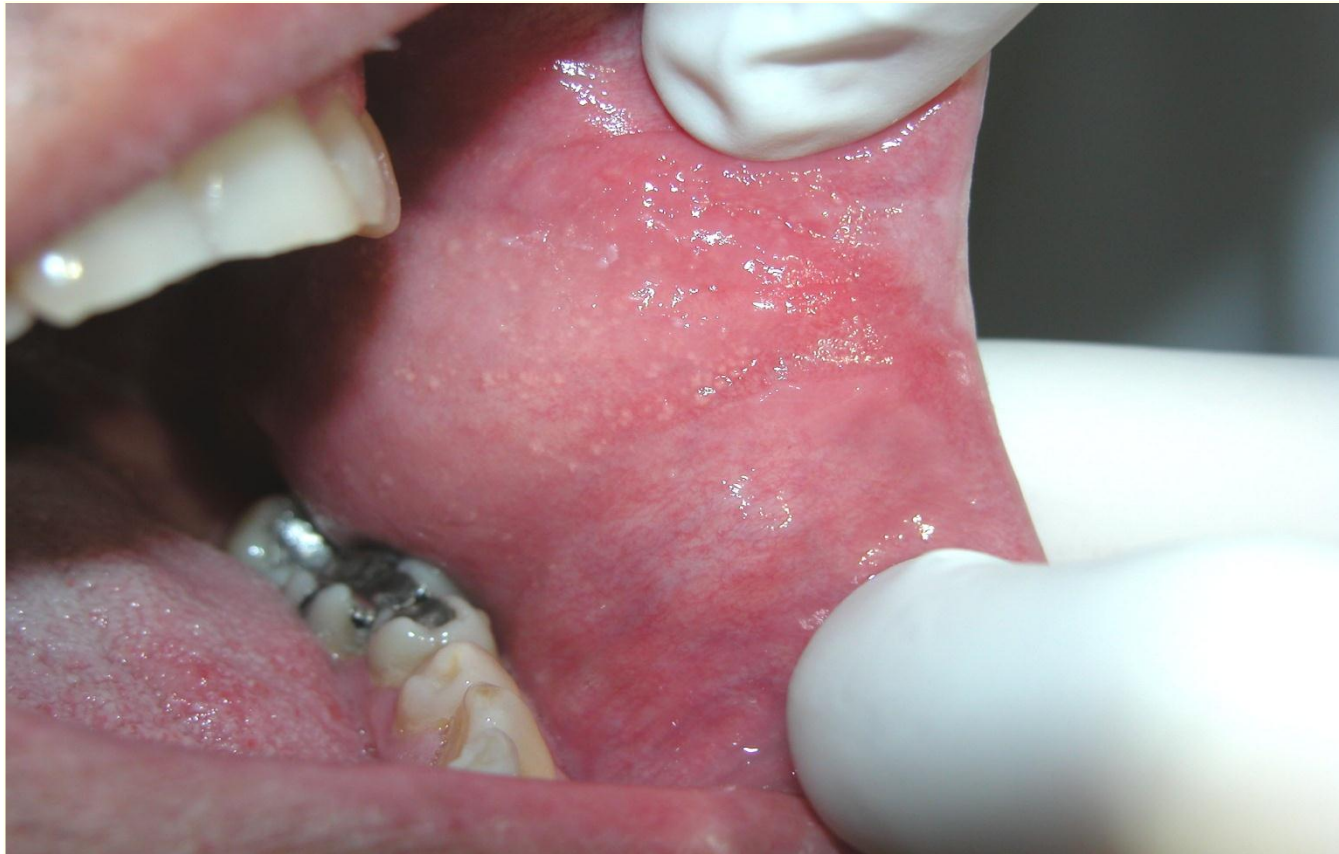Neville et al (2004)

Grânulos de Fordyce

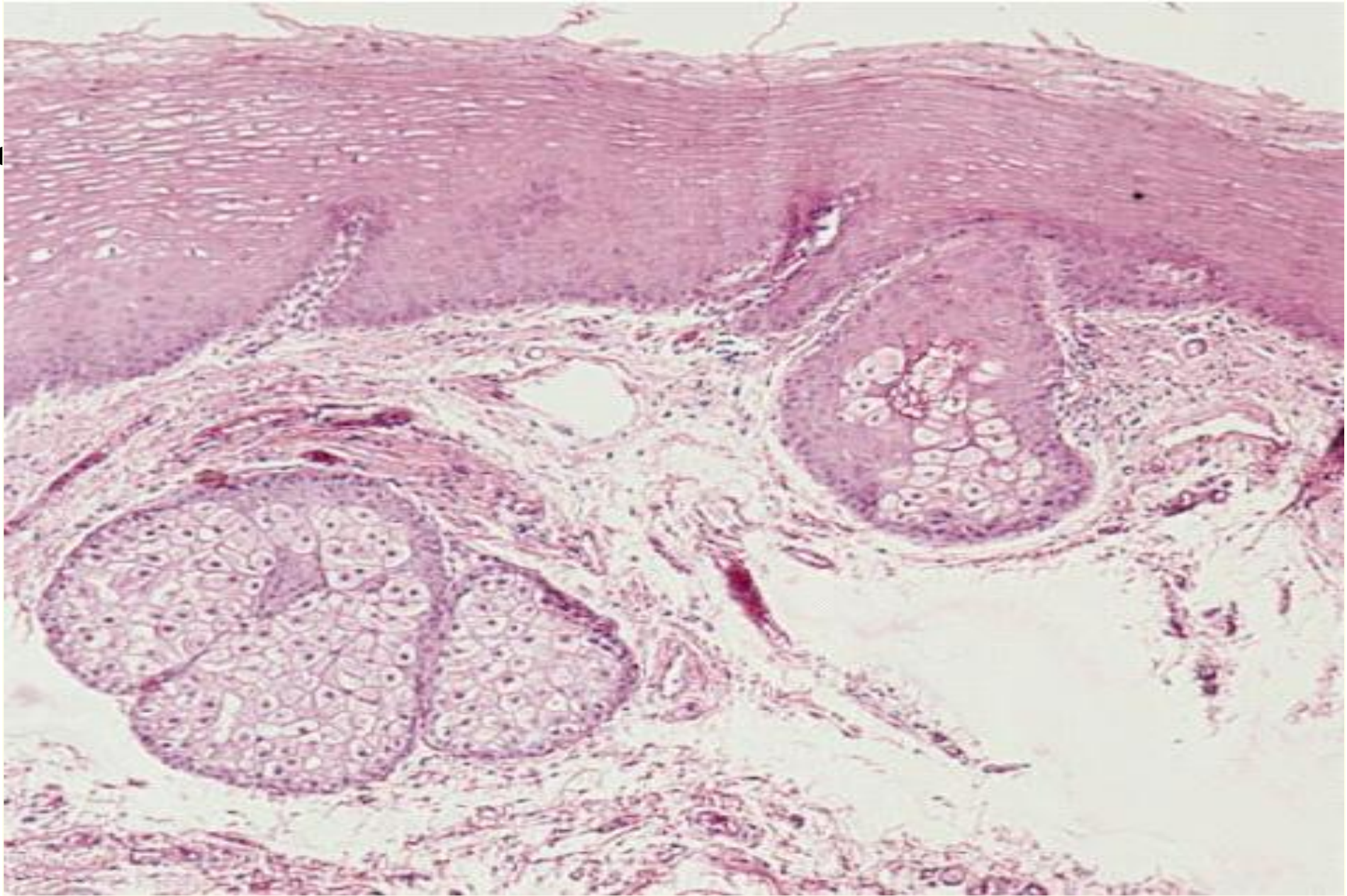


Neville et al (2004)

- Granulos de Fordyce

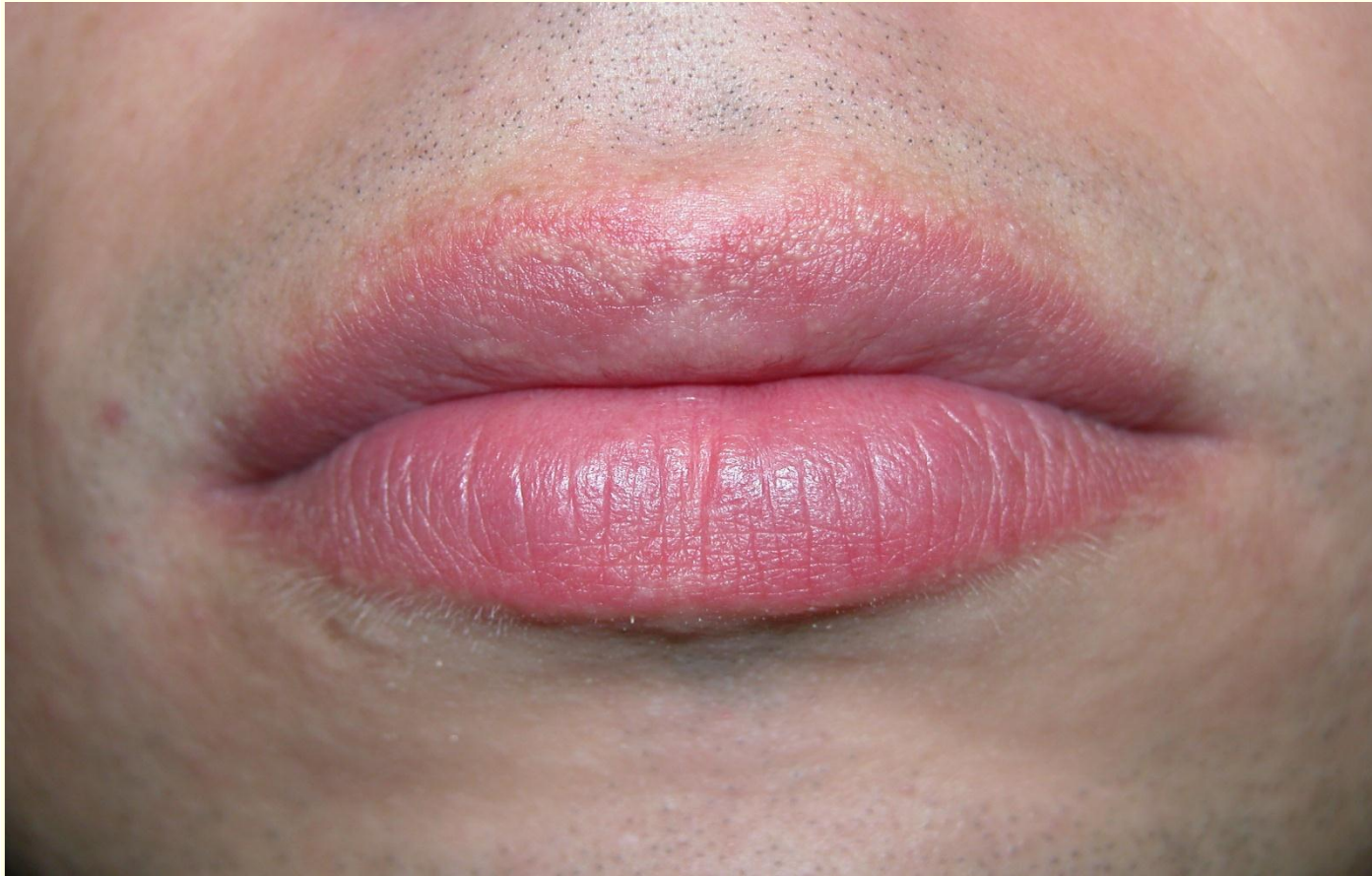

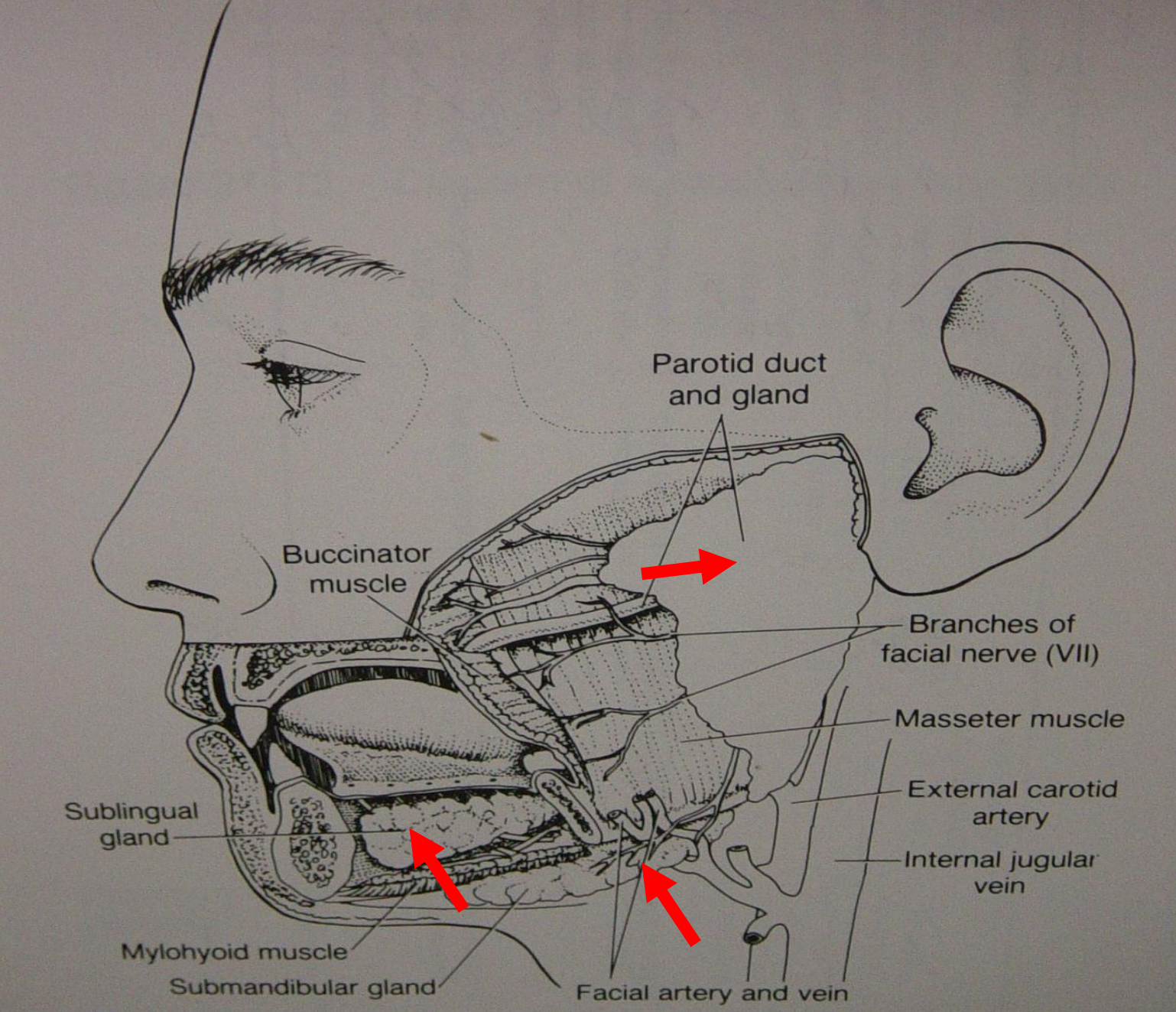
Grânulos de Fordyce



Grânulos de Fordyce

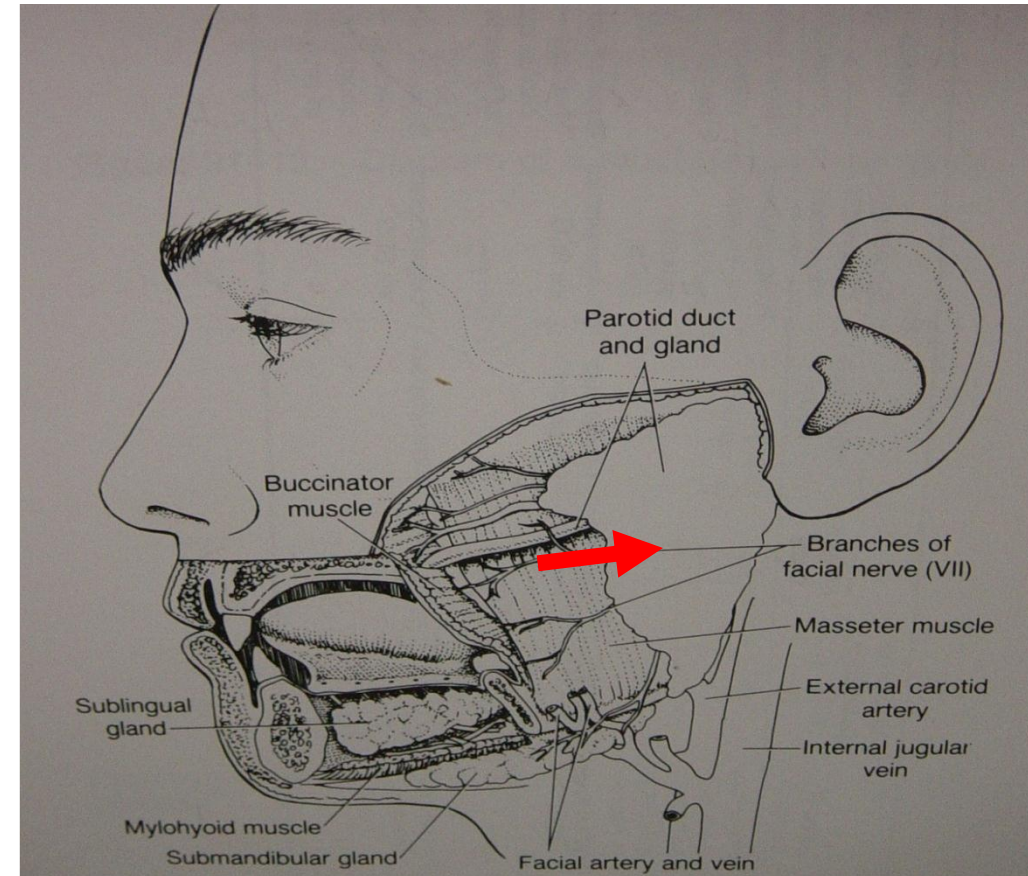
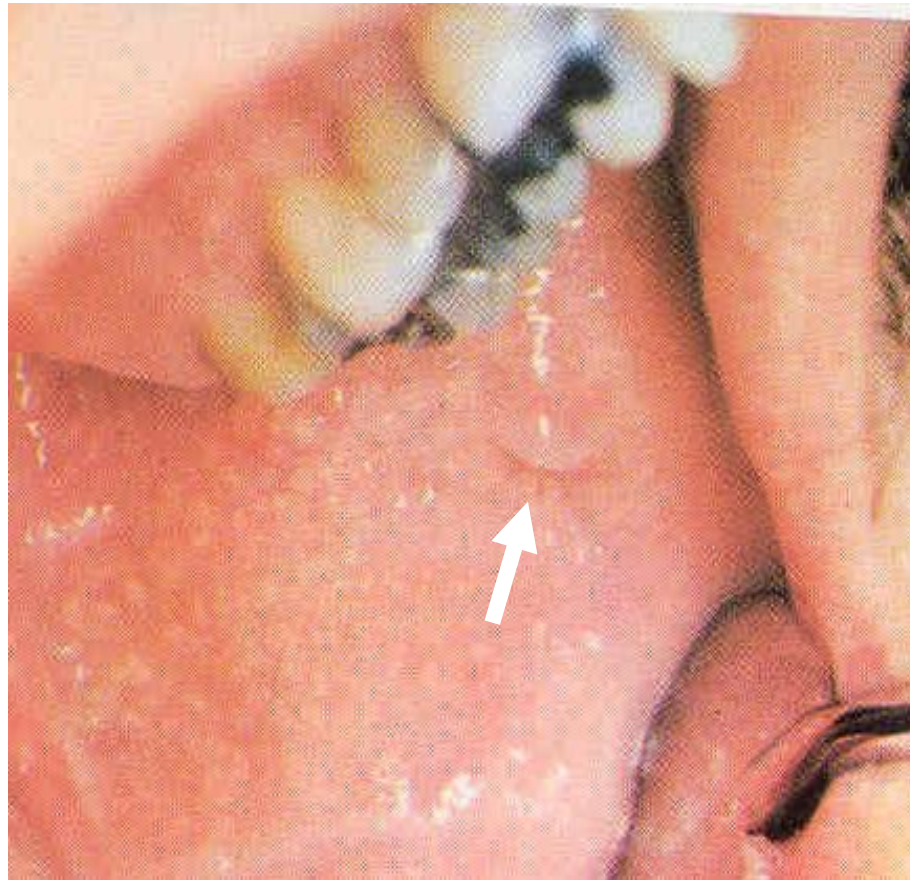
- Granulos de Fordyce



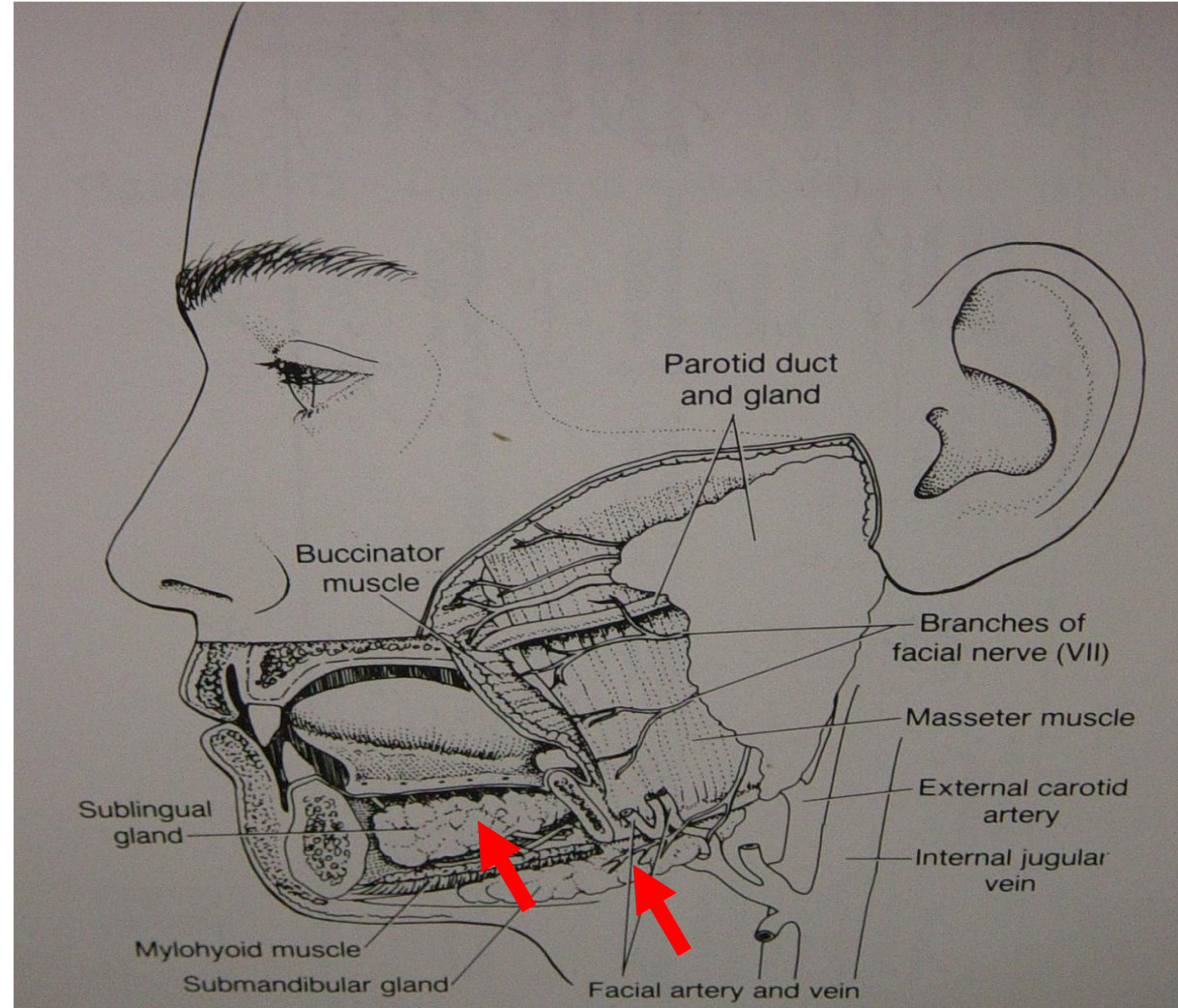
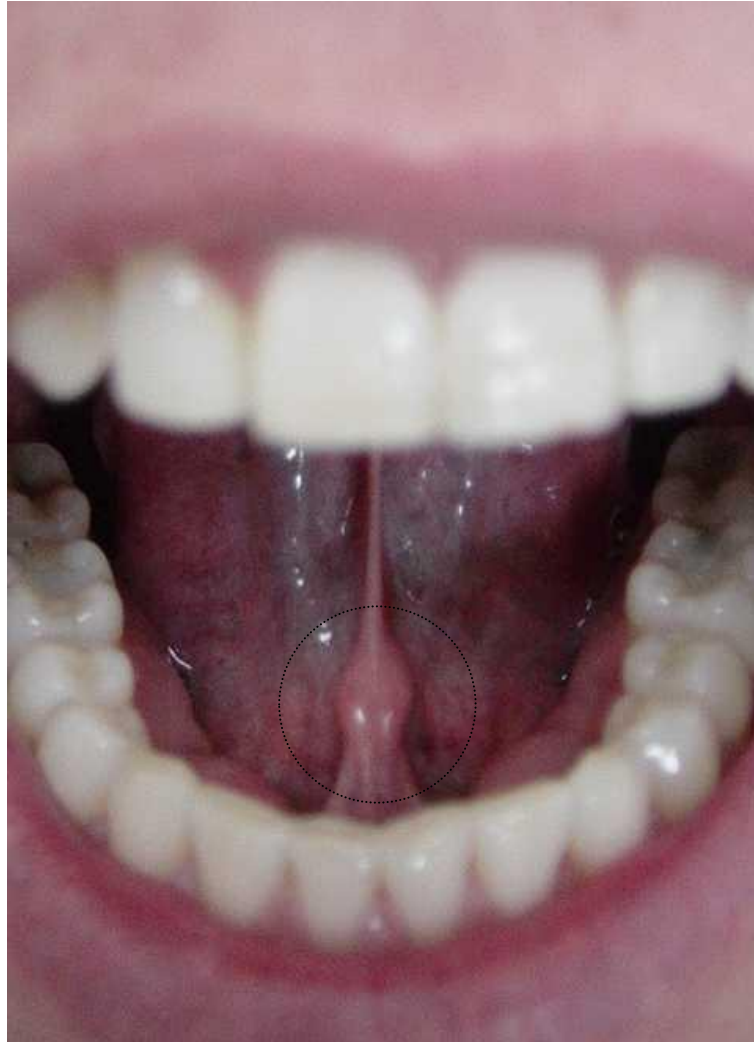

Papila parotídea

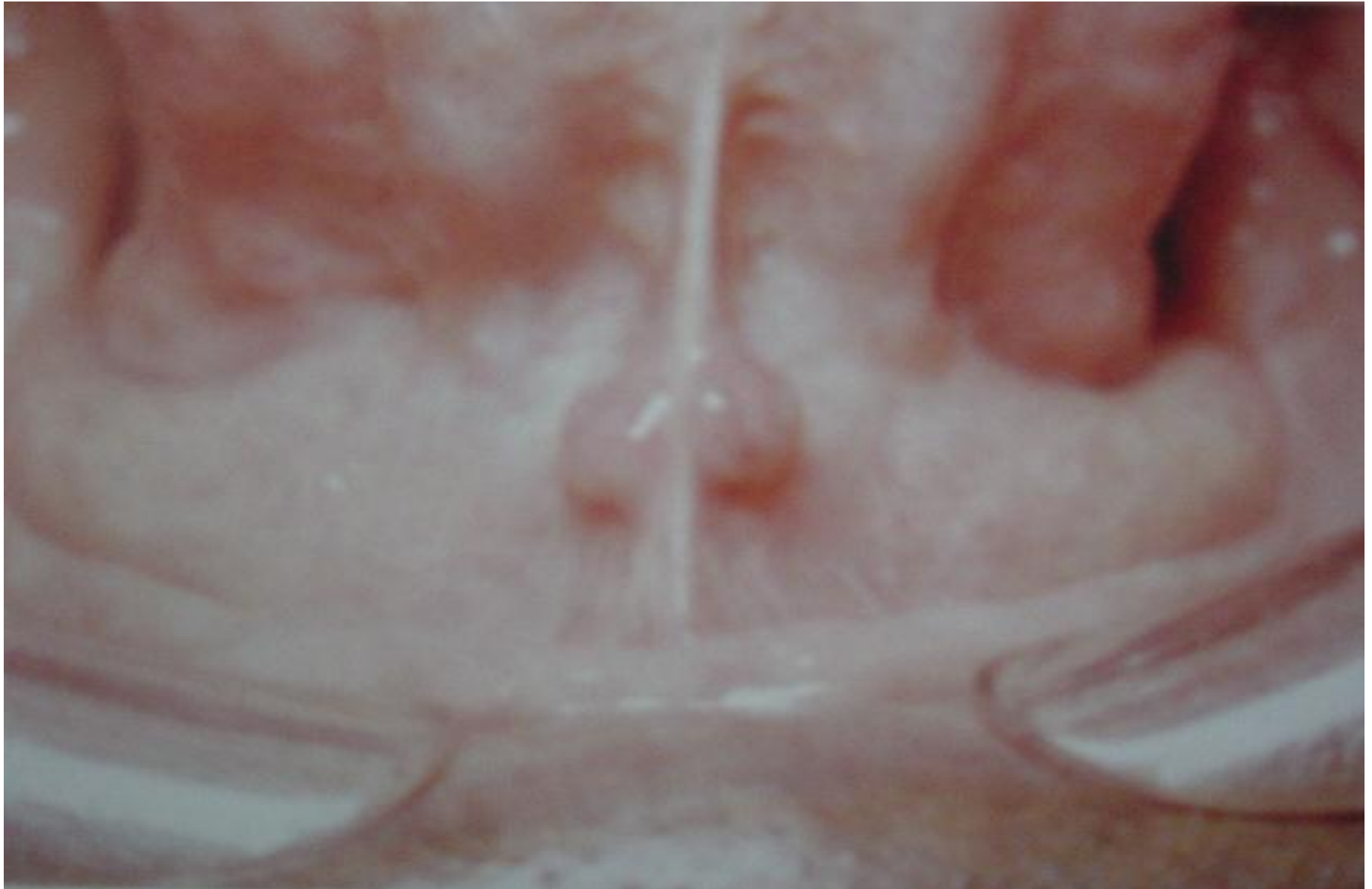Ducto de Stenon (Stensen)



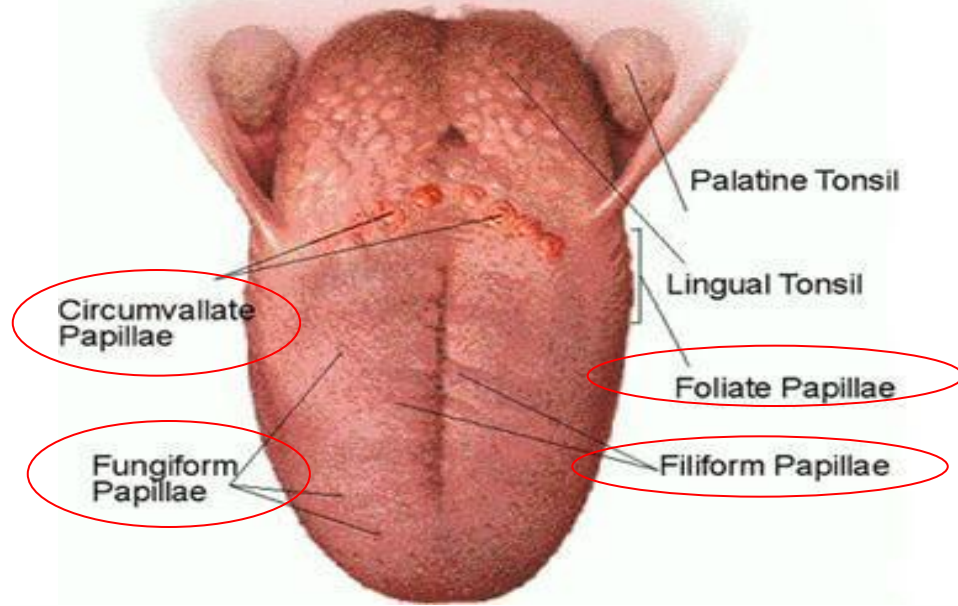
Carúncula sublingual



Carúncula sublingual

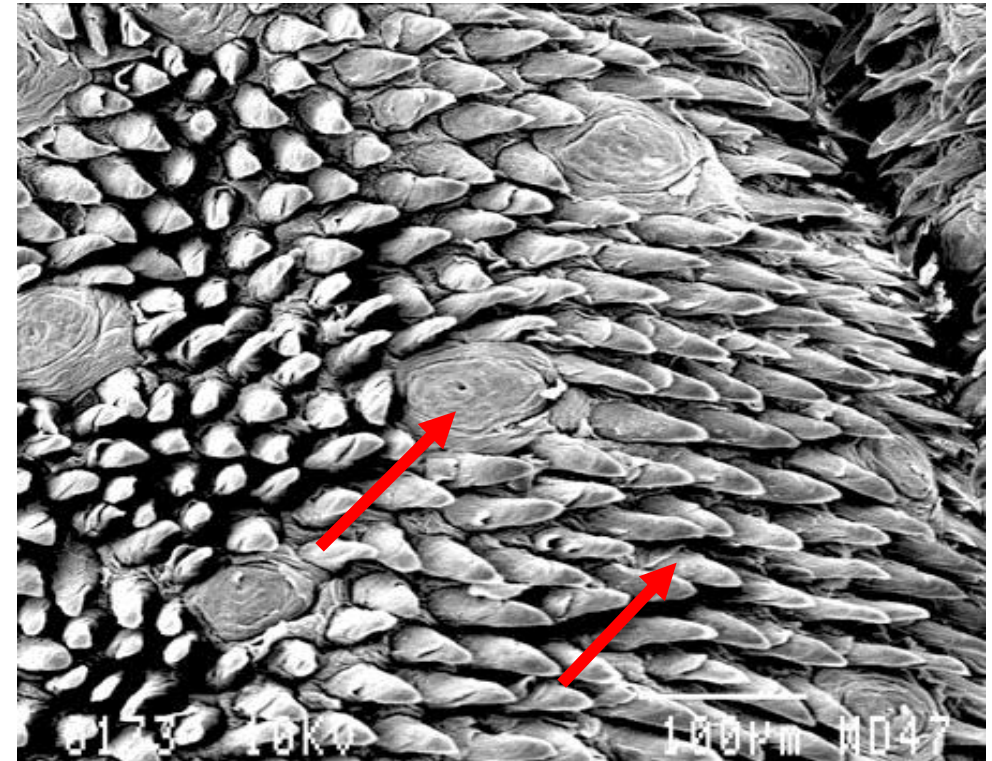


Tongue

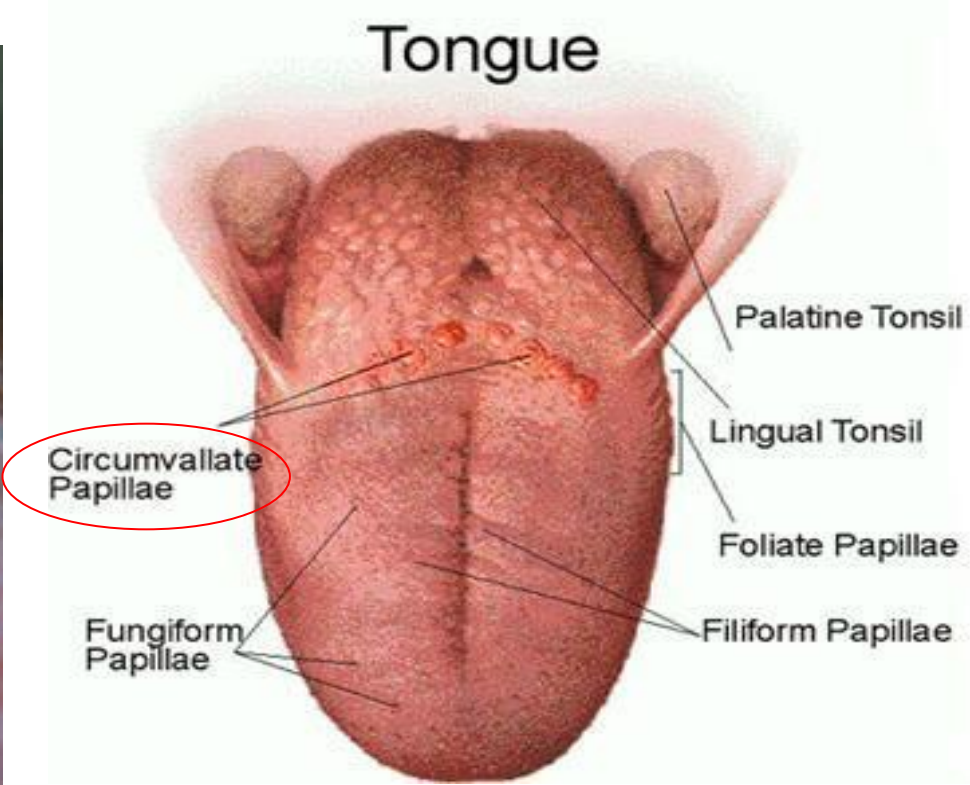
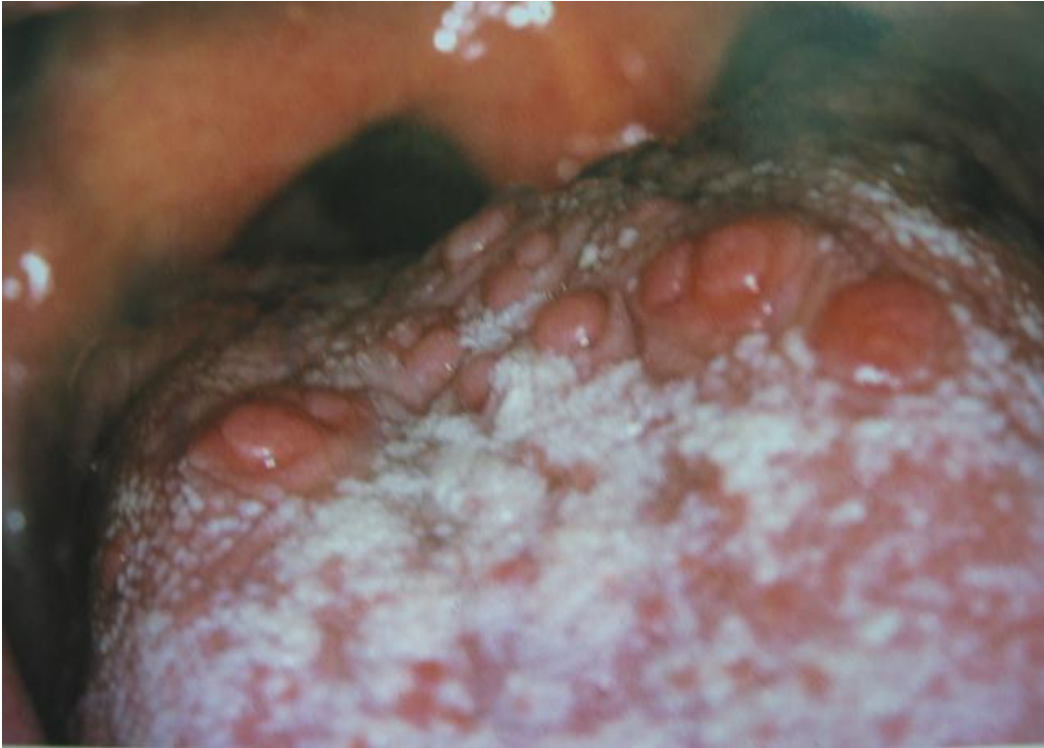

www.doctorspiller.com

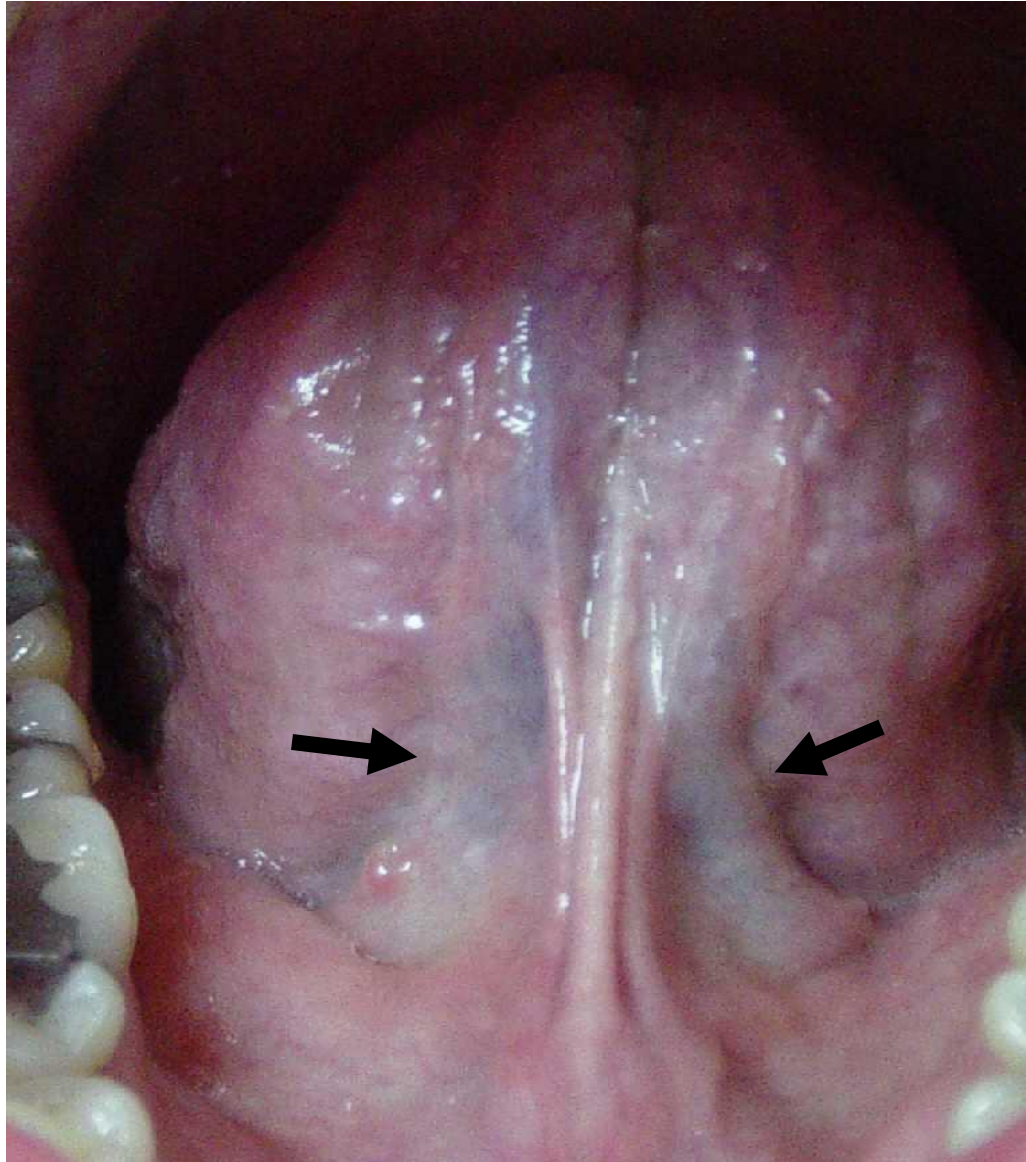
http://www.trincoll.edu/~alehman/PhotoBIOL210_03.htm



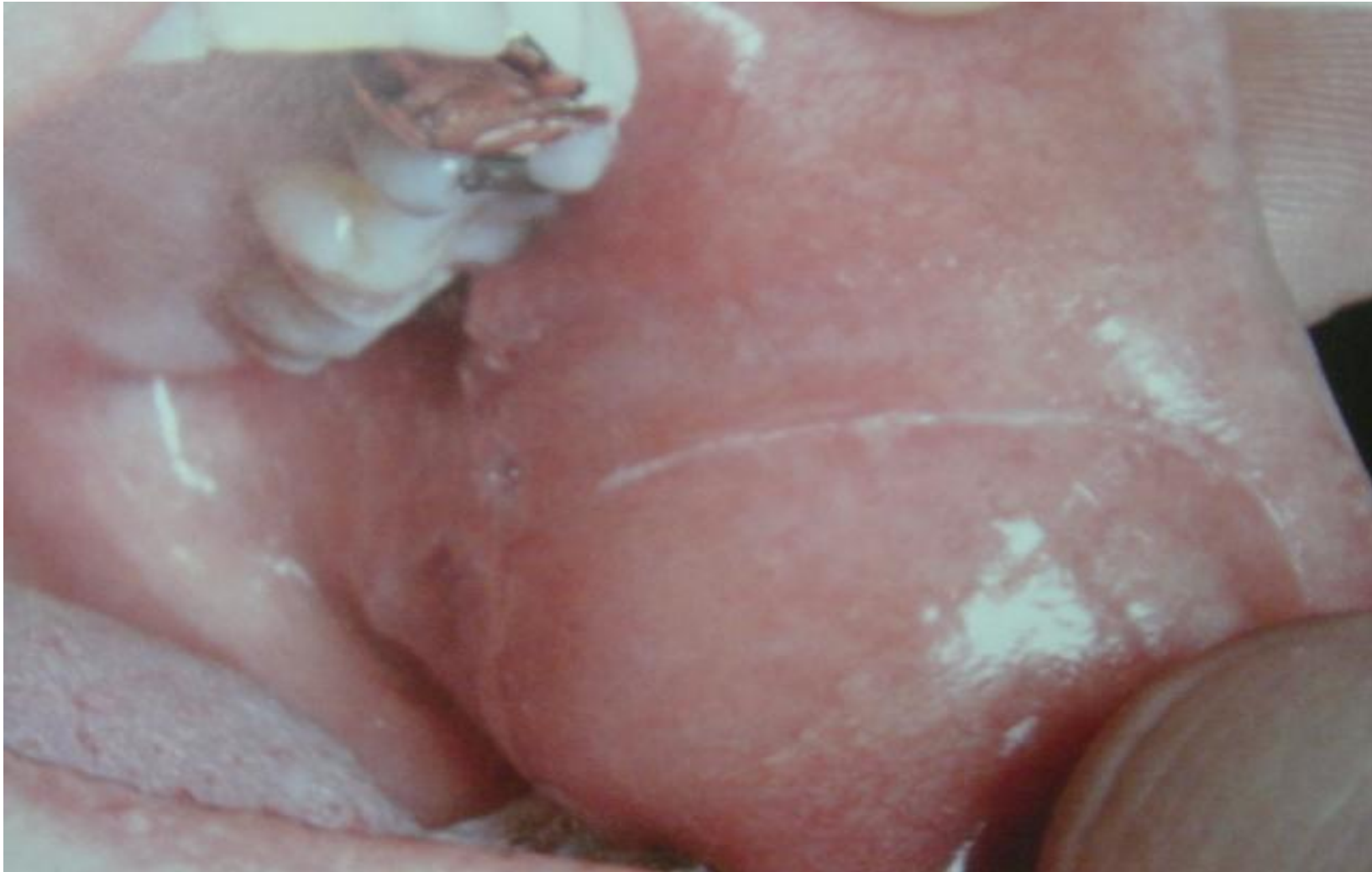Papilas circunvaladas



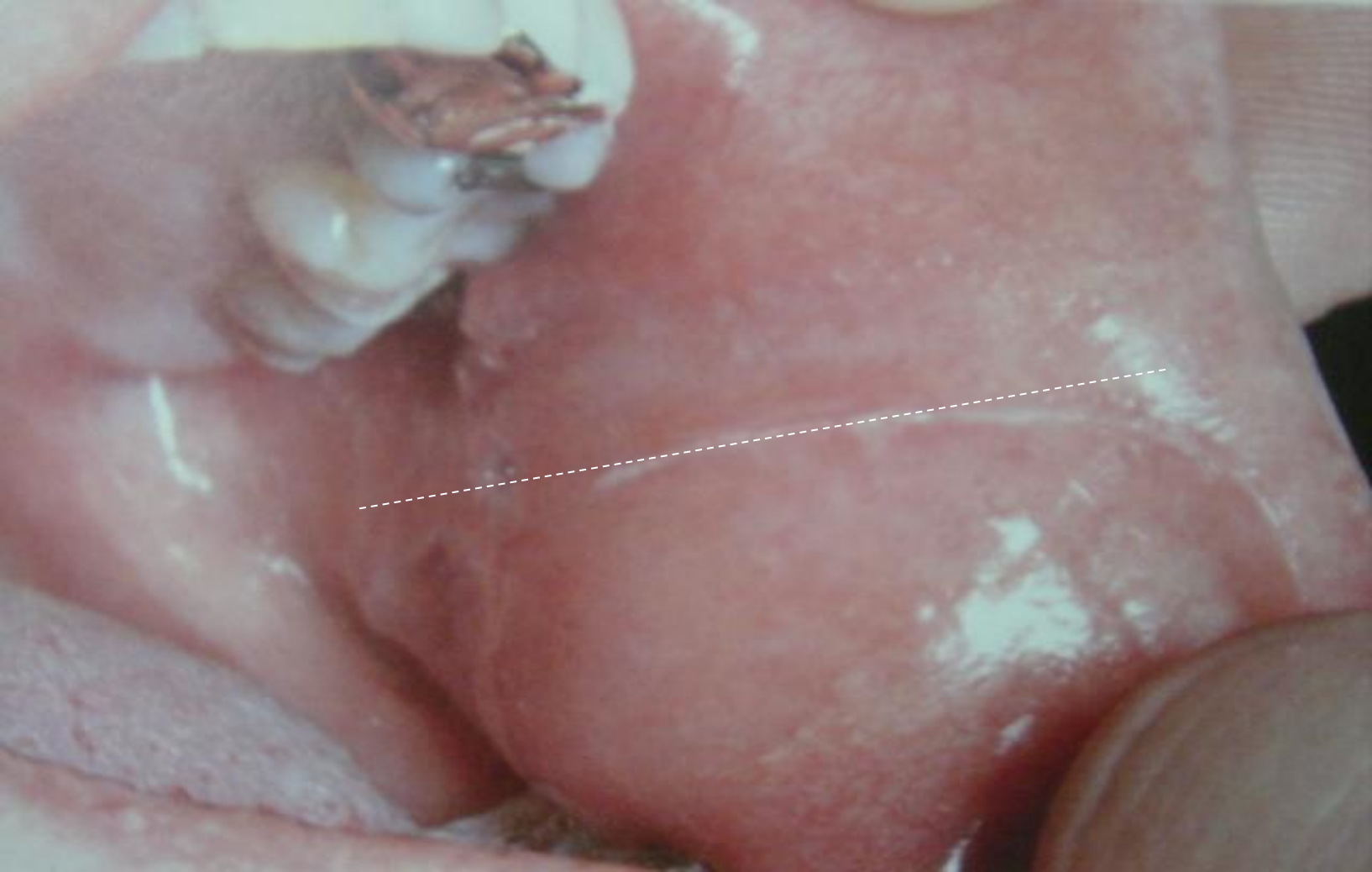Pregas fimbriadas



Linha Alba



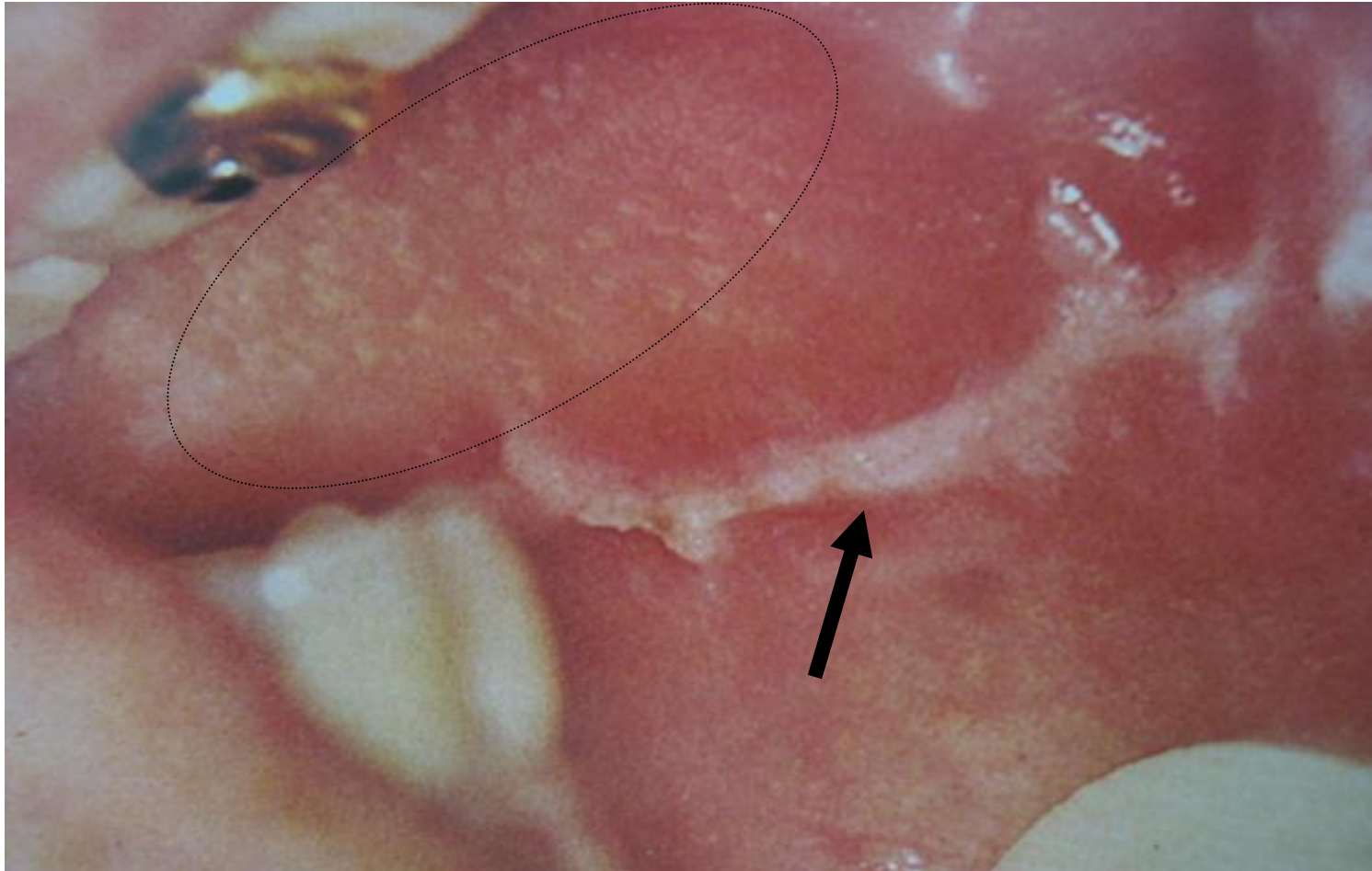
Linha Alba



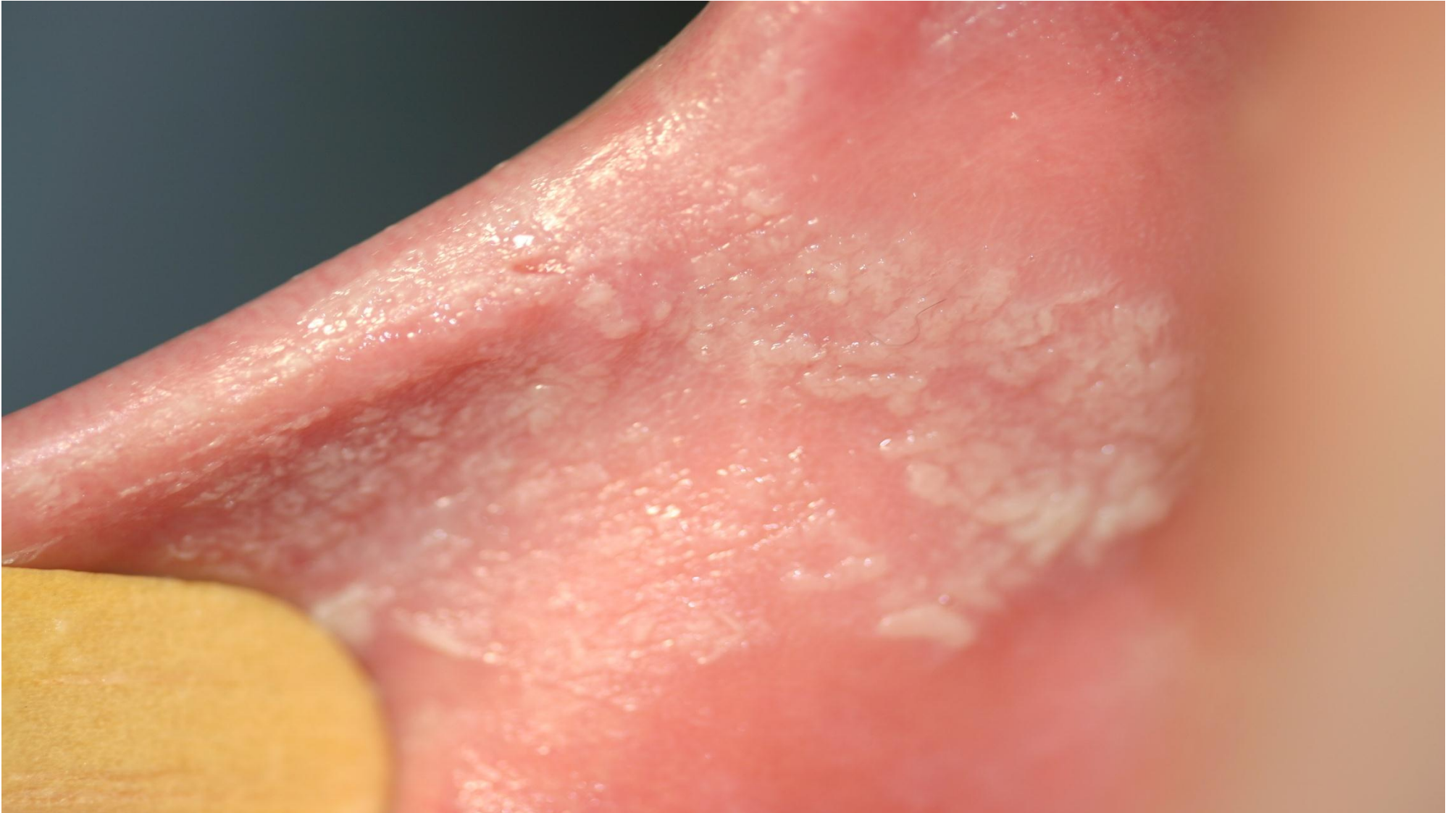Linha Alba



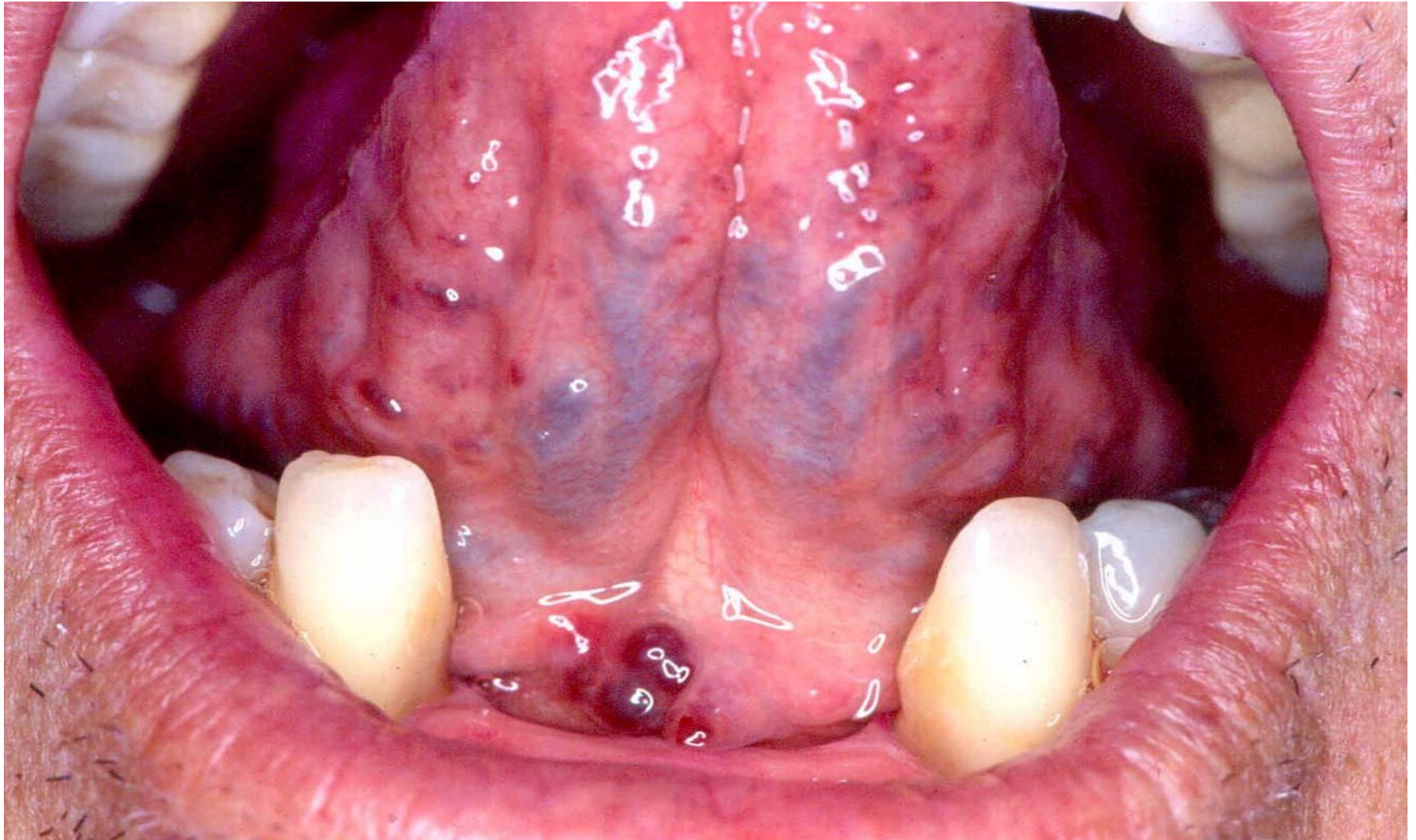
Linha Alba



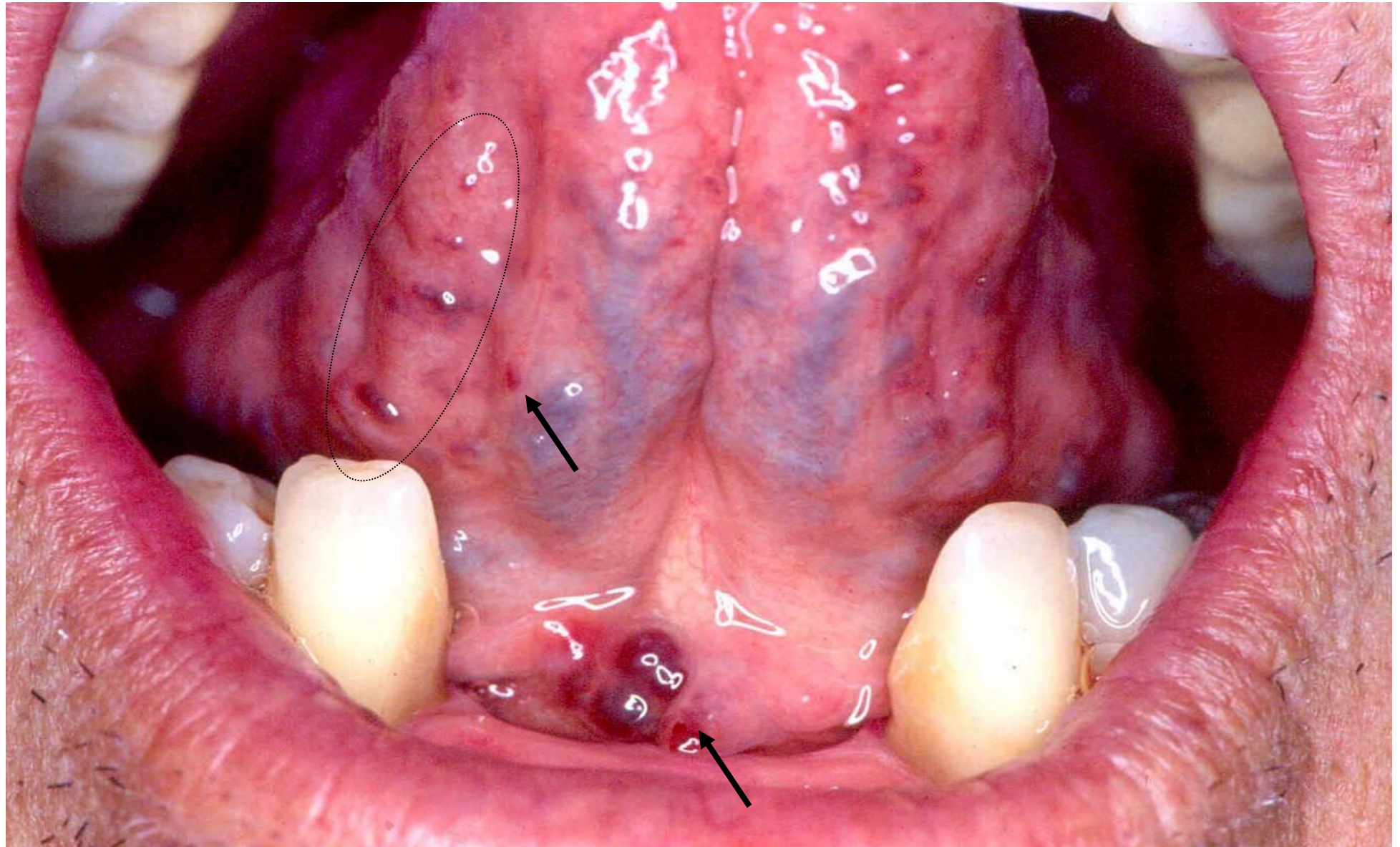
- Mucosa mordiscada



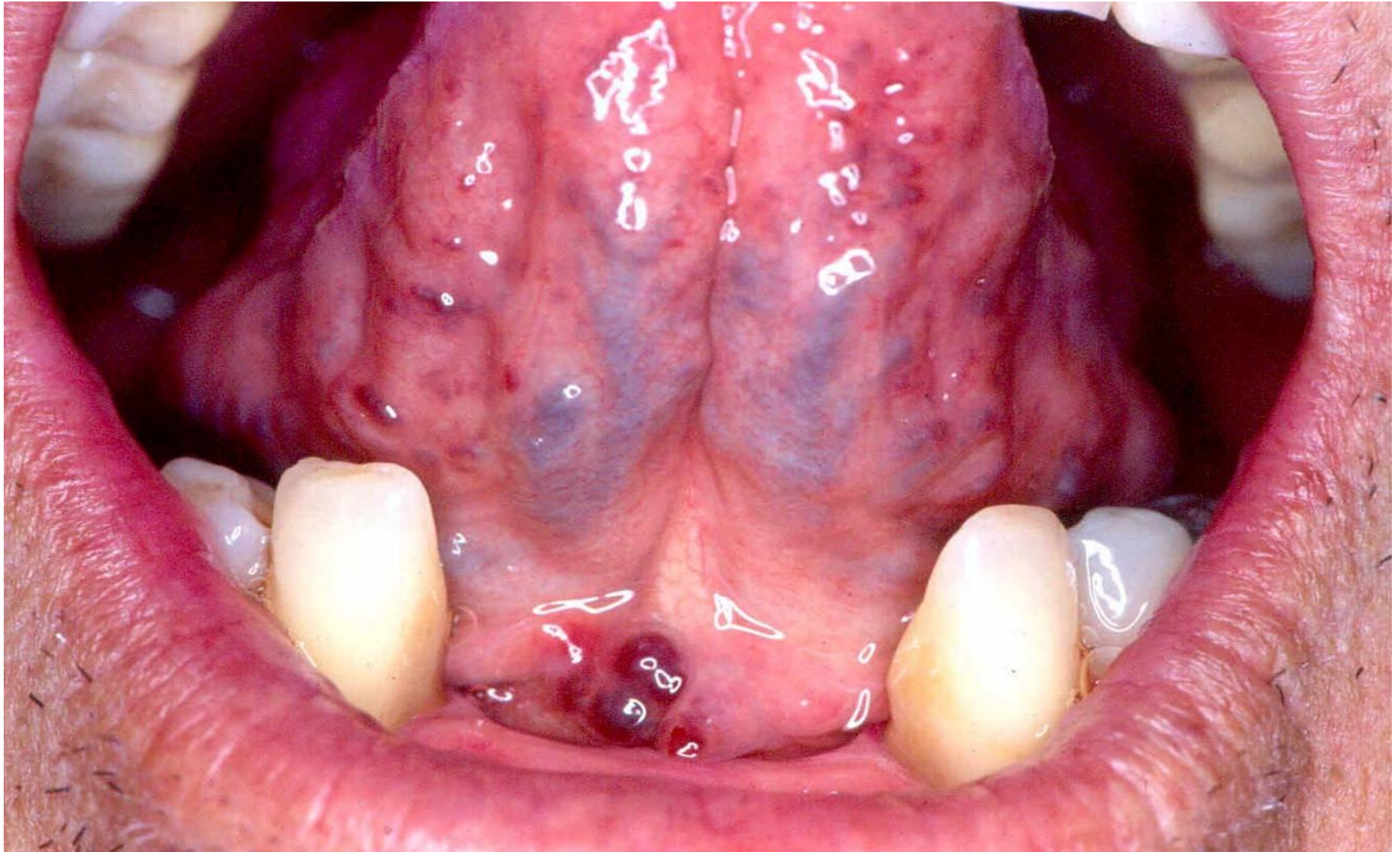
Varicosidades linguais



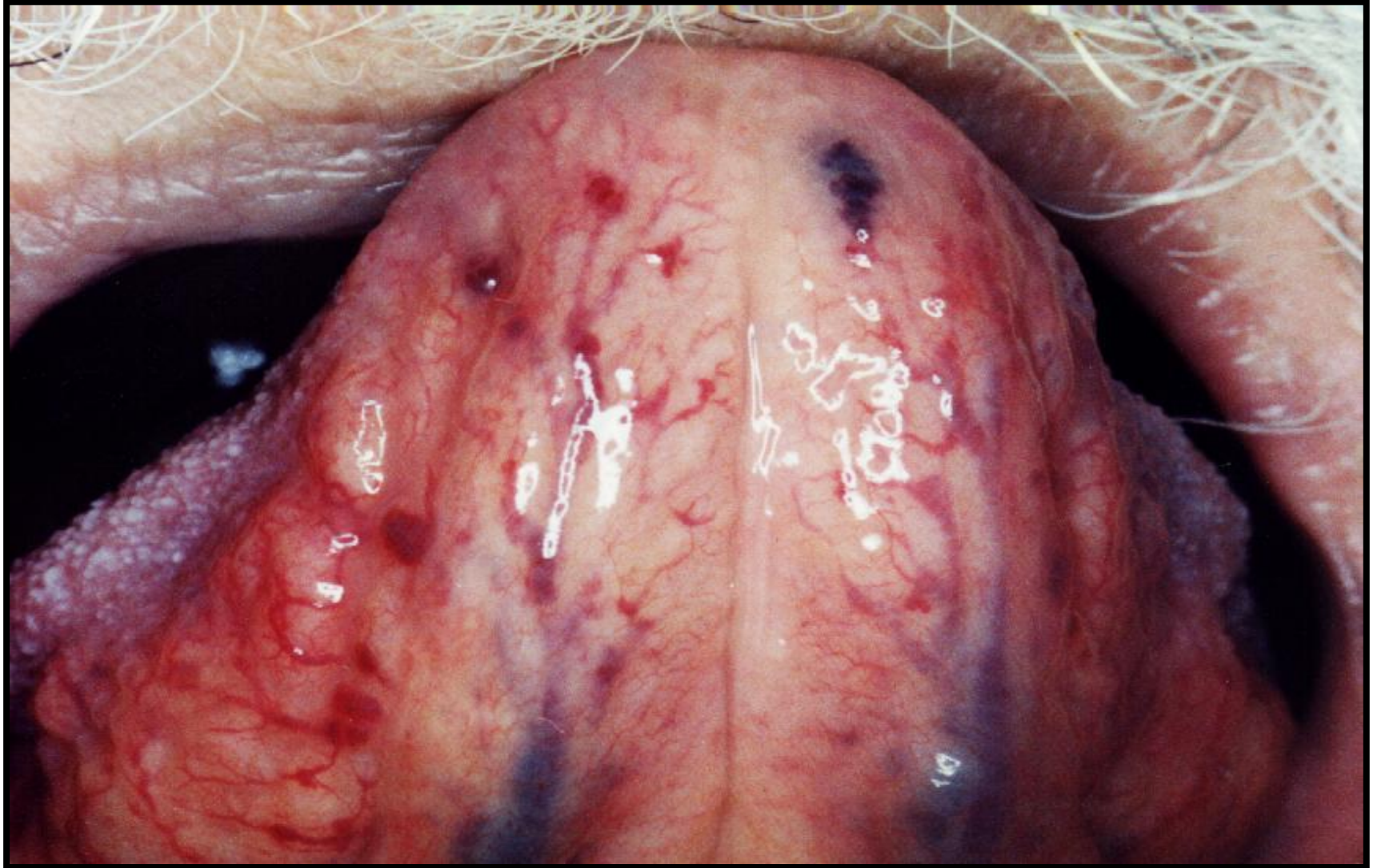
Varicosidades linguais



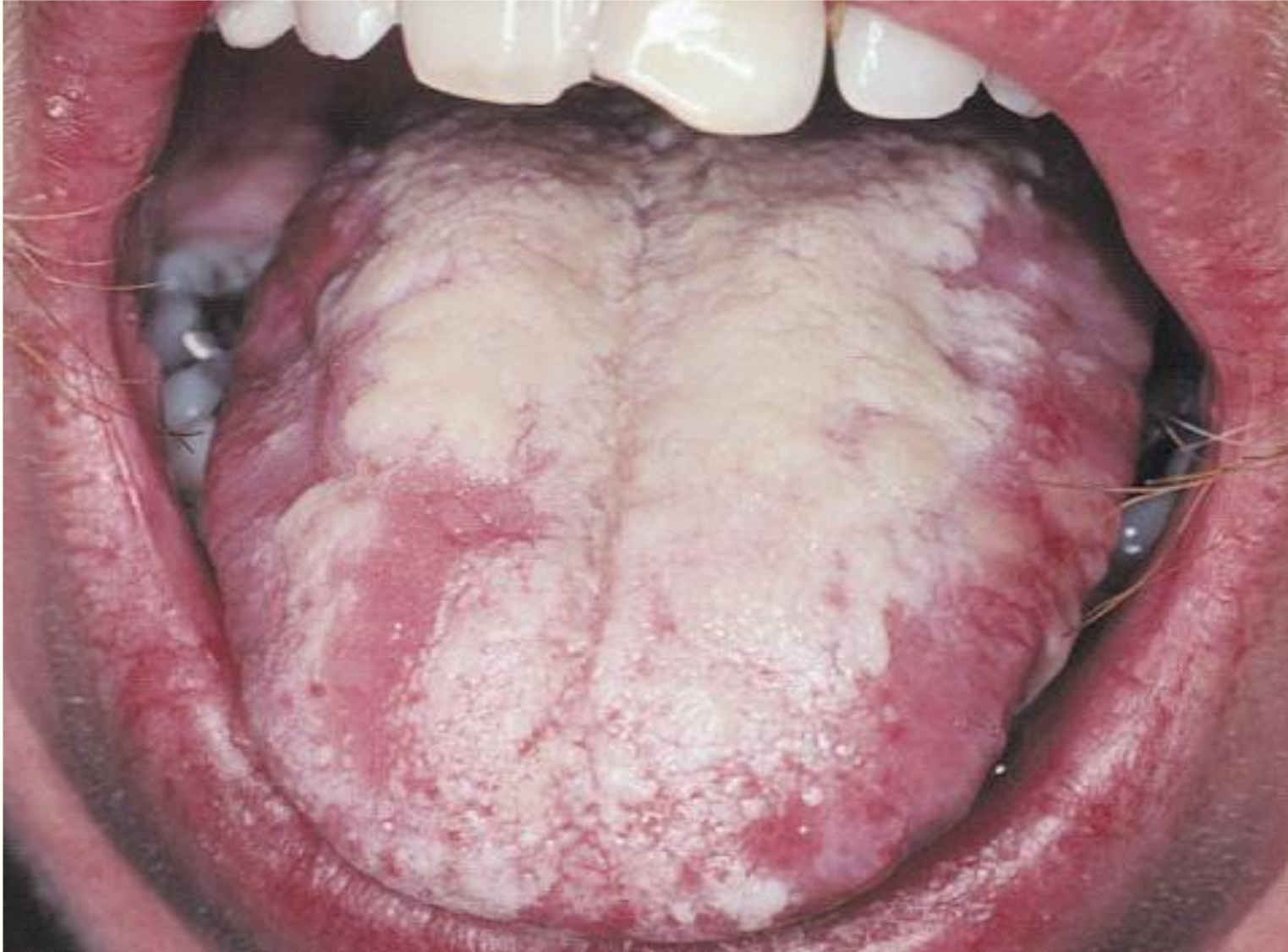Varicosidades linguais



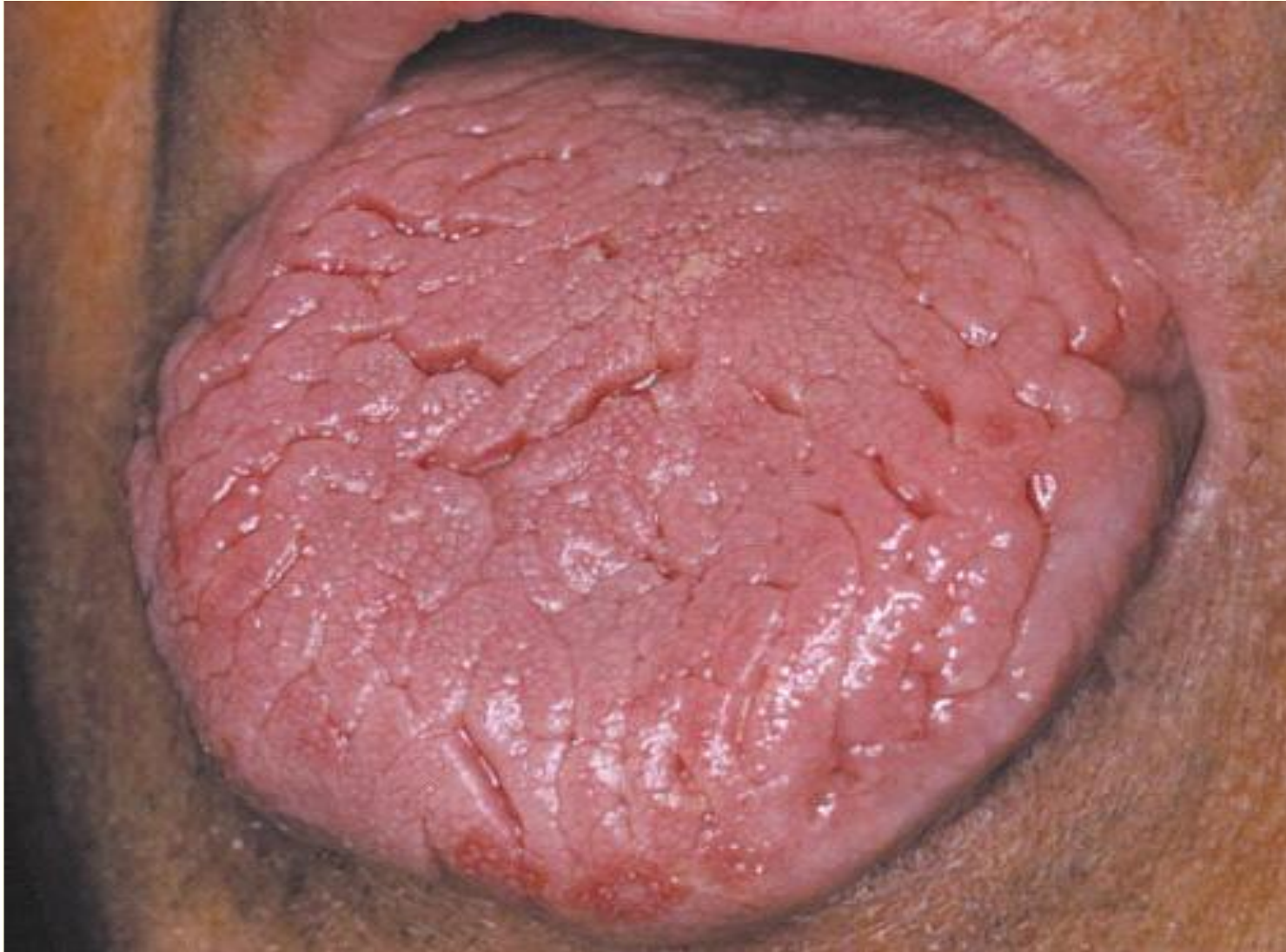Varicosidades linguais



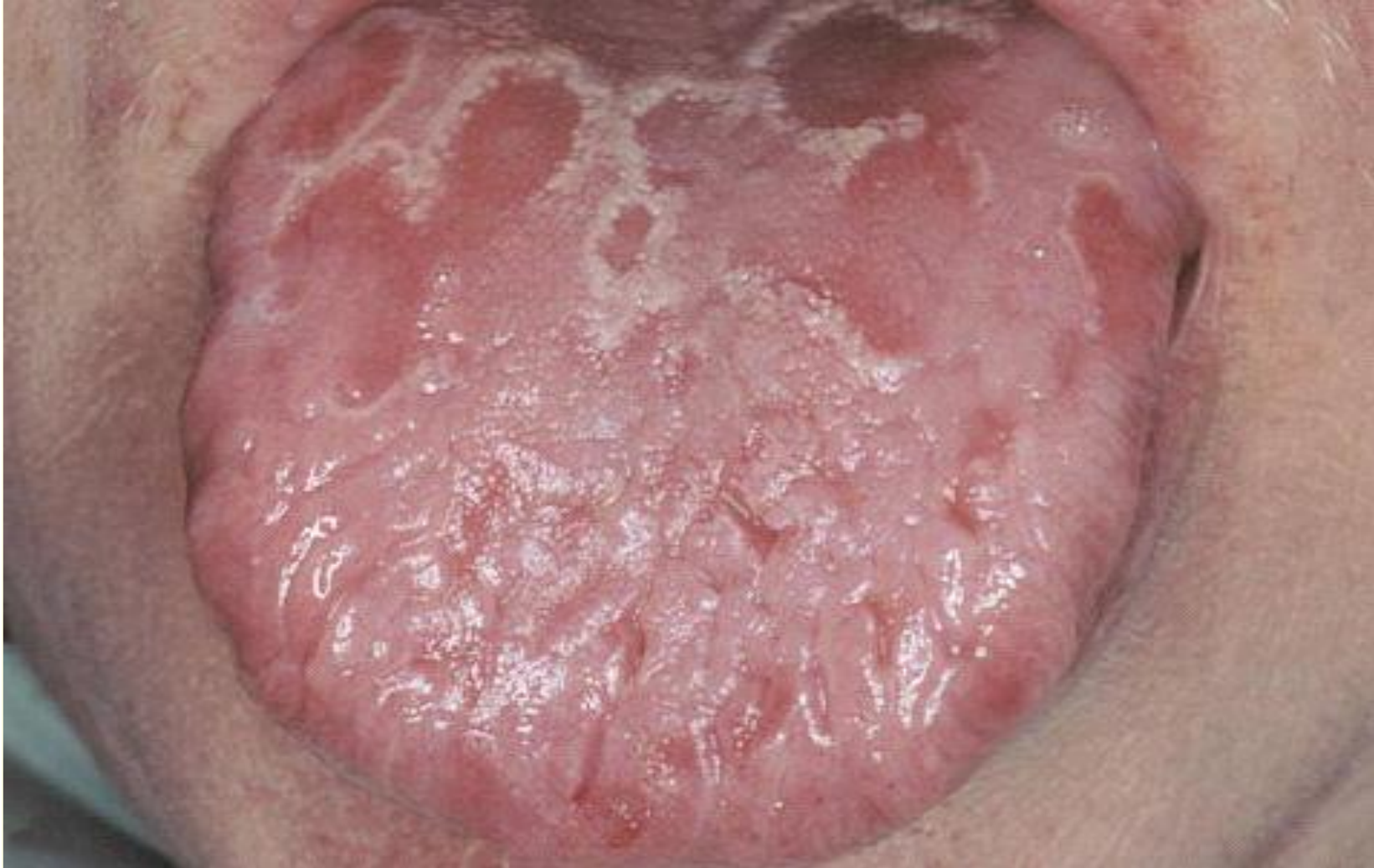- Saburra lingual



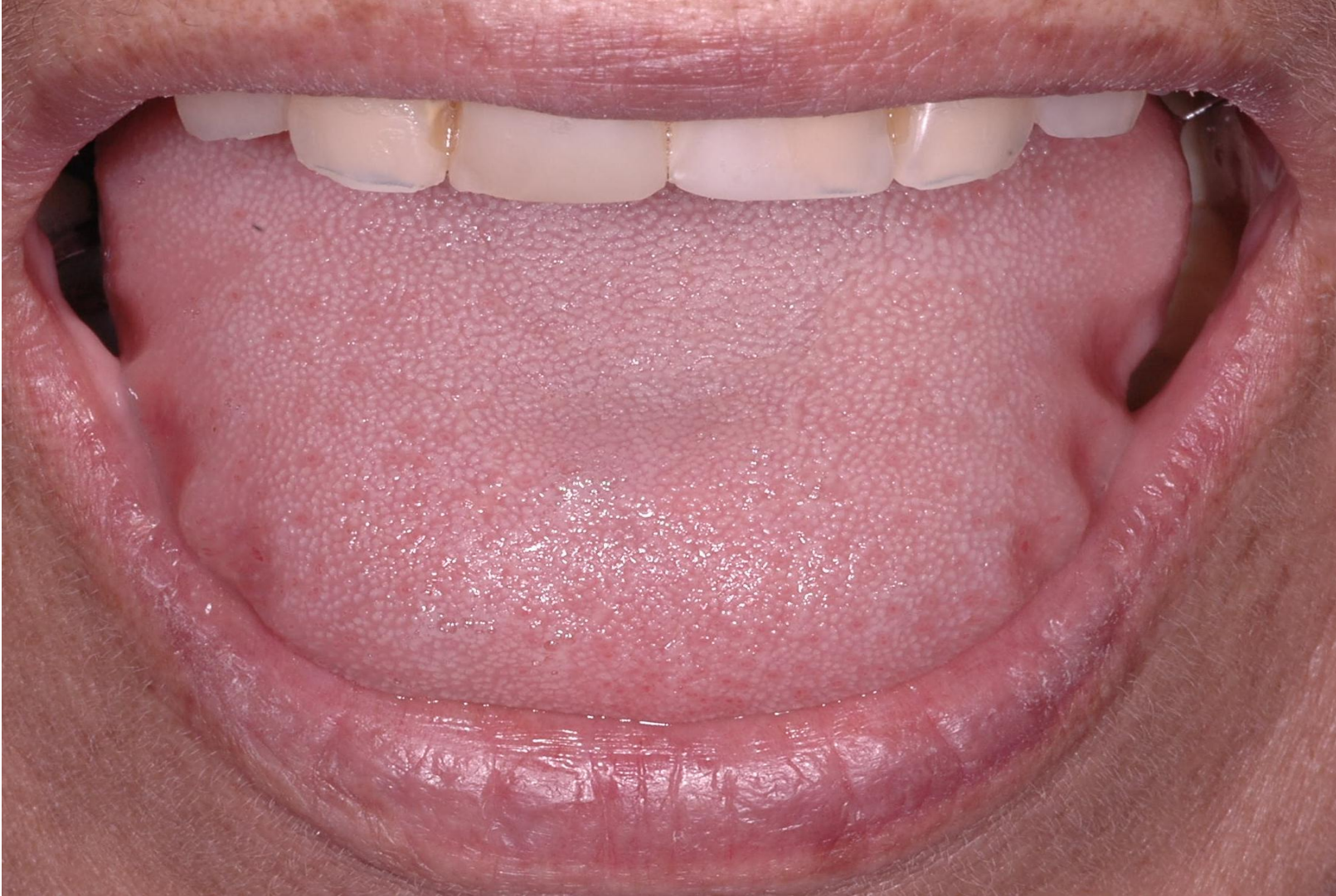- **Lingua Fissurata**



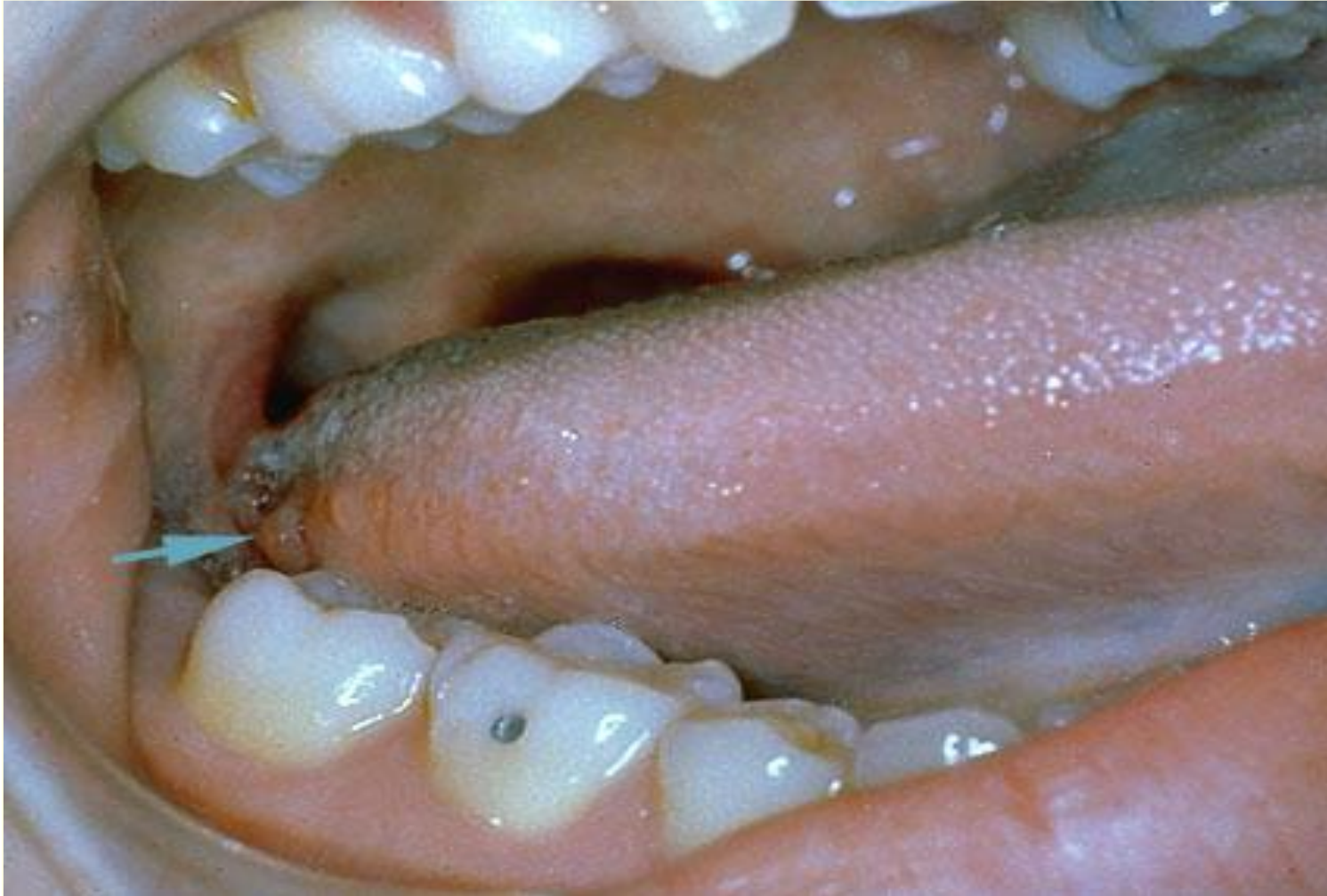- **Lingua geográfica**



- Lingua Crenada



- Papilas foliadas



- Estomatite nicotínica

